

# Challenges Associated with the Endo-Bentall Approach

**Stéphan Haulon, D. Fabre, J. Guihaire,  
T. Le Houérou, A. Gaudin, A. Costanzo**

**Aortic Center**

HÔPITAUX Paris

Saint-Joseph

Marie-Lannelongue



**université**  
**PARIS-SACLAY**



THE 27<sup>TH</sup> INTERNATIONAL EXPERTS SYMPOSIUM

# CRITICAL ISSUES

IN AORTIC ENDOGRAFTING

---

MARCH 20 & 21 2025

HYATT REGENCY ETOILE, PARIS

COURSE LOCAL ORGANIZERS

Stéphan Haulon, **Paris, France**

Tara Mastracci, **London, United Kingdom**

CRITICAL ISSUES STEERING COMMITTEE


Nuno Dias, **Malmö, Sweden**

Athanasios Katsargyris, **Nuremberg, Germany**

Timothy Resch, **Copenhagen, Denmark**

Eric Verhoeven, **Nuremberg, Germany**

# Disclosures



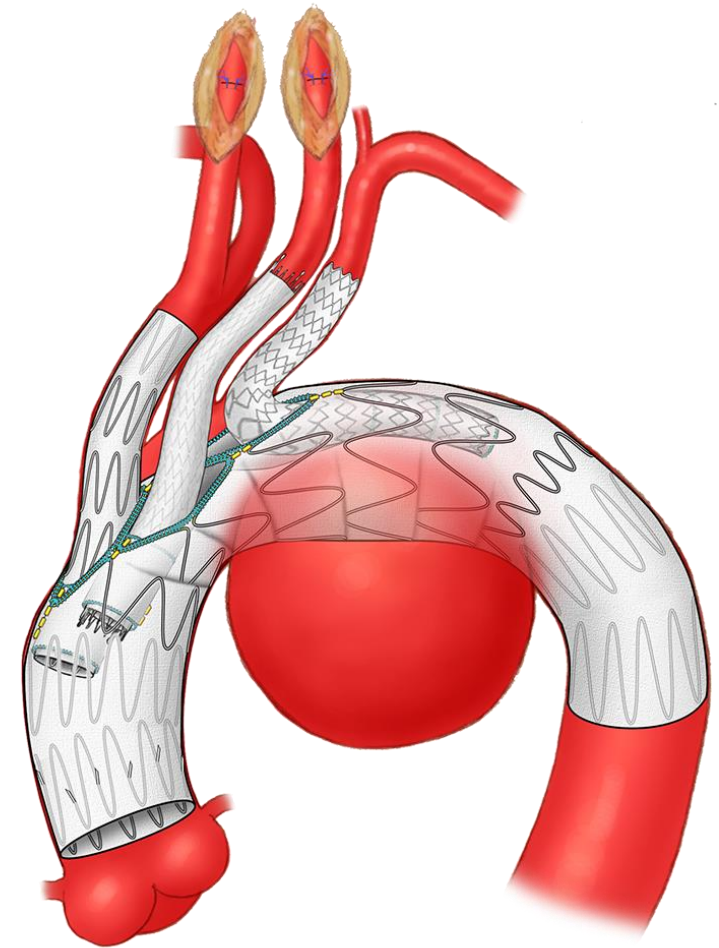
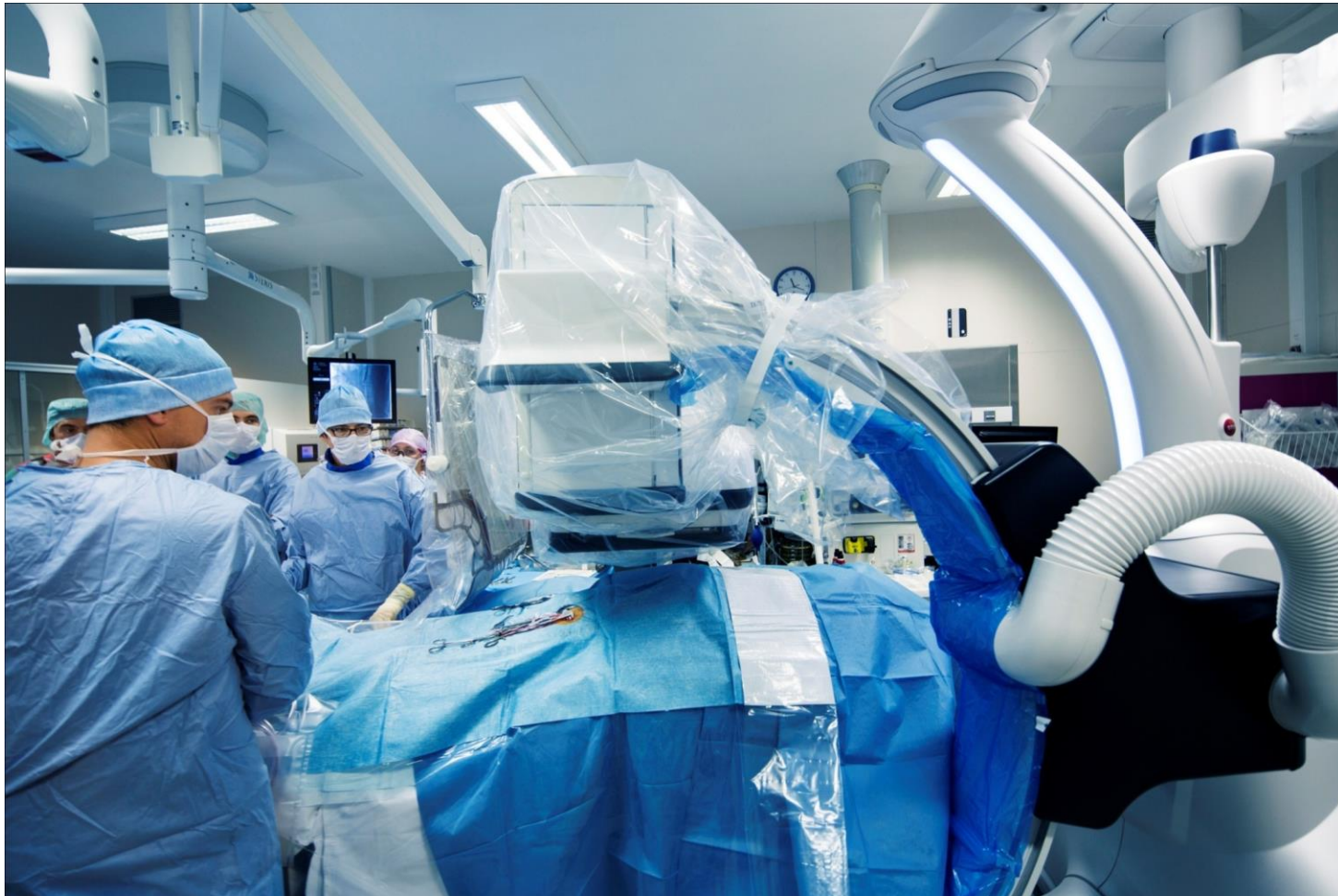- Research support, Consulting
  - Cook Medical, GE Healthcare, Bentley

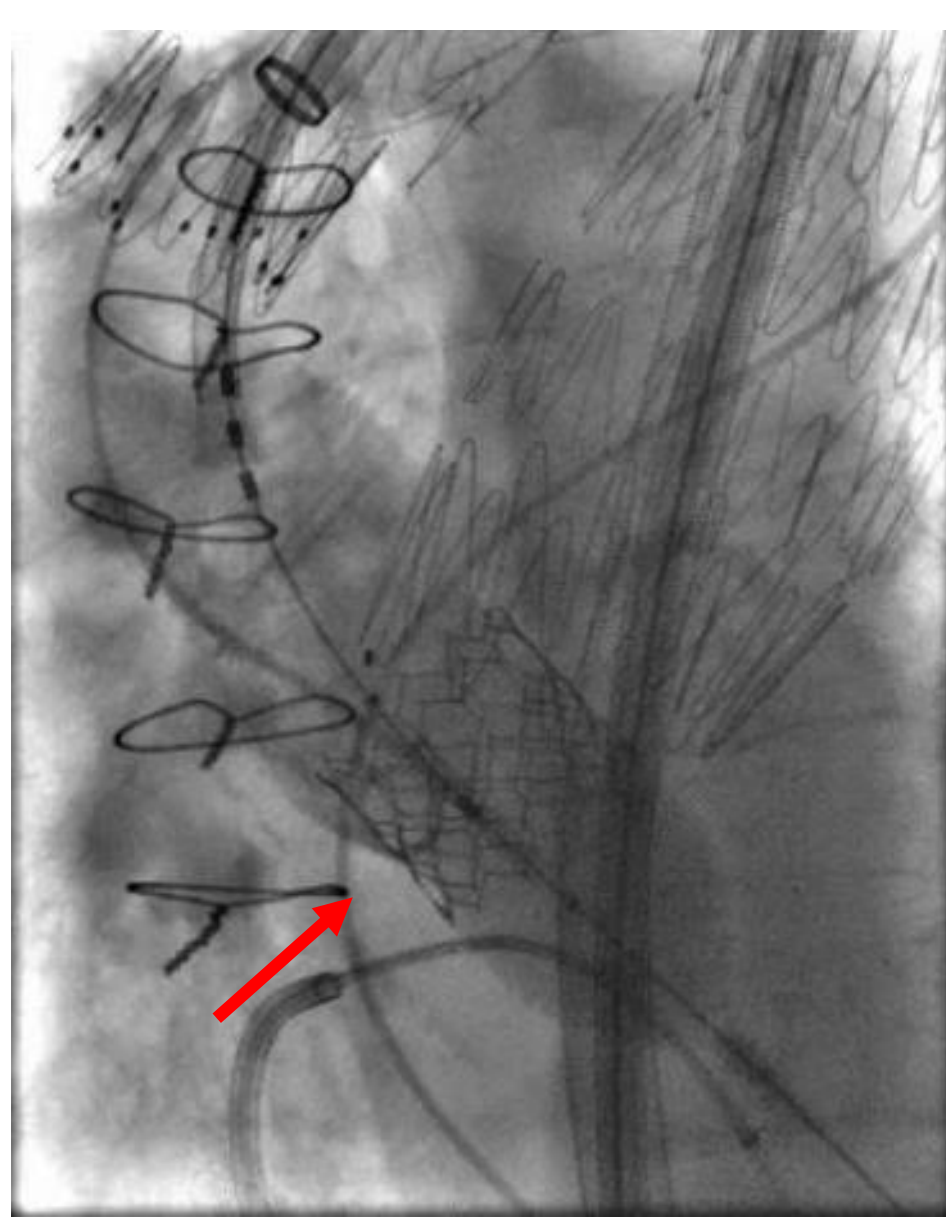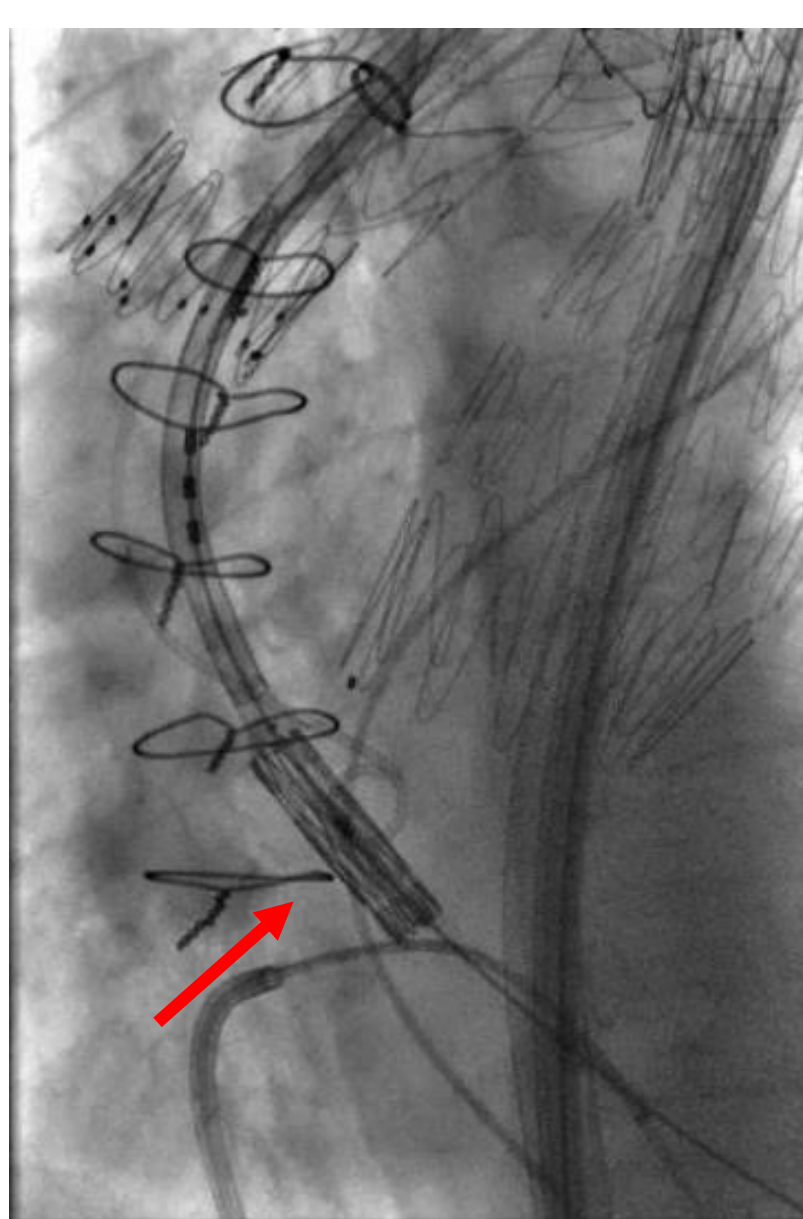
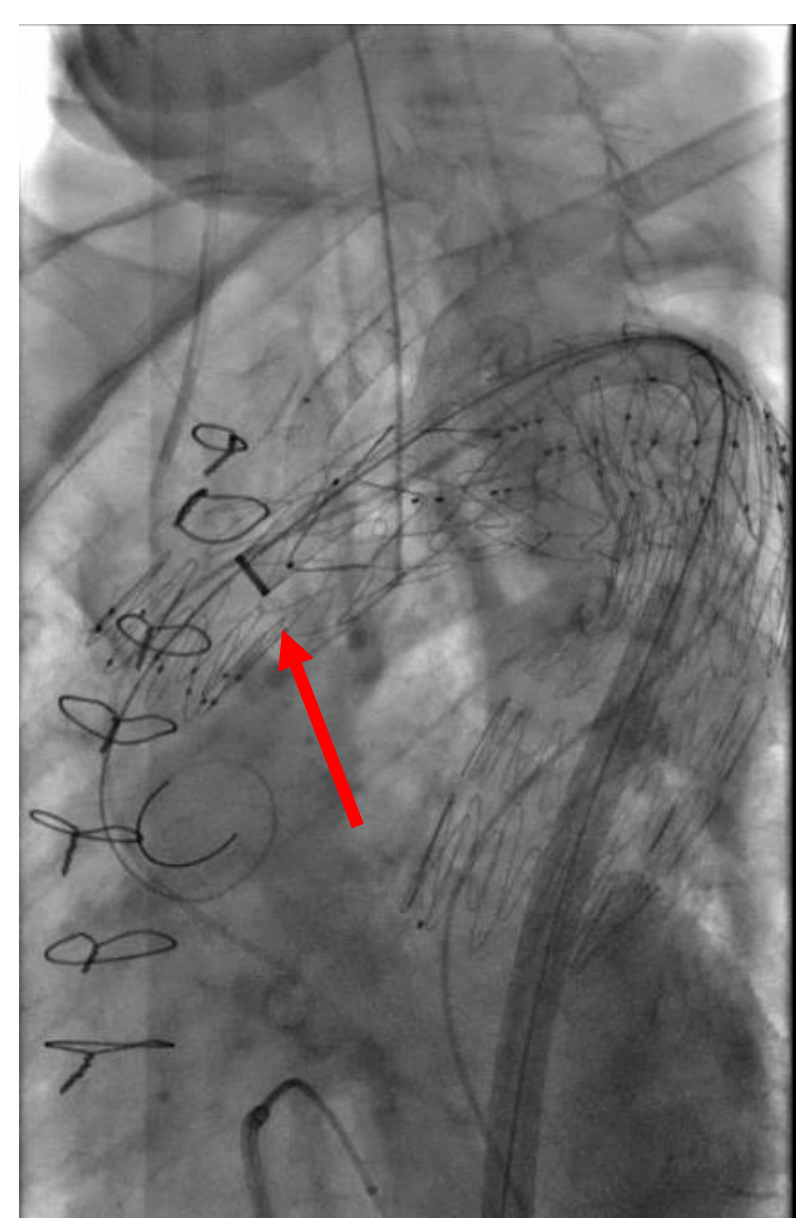HÔPITAUX Paris

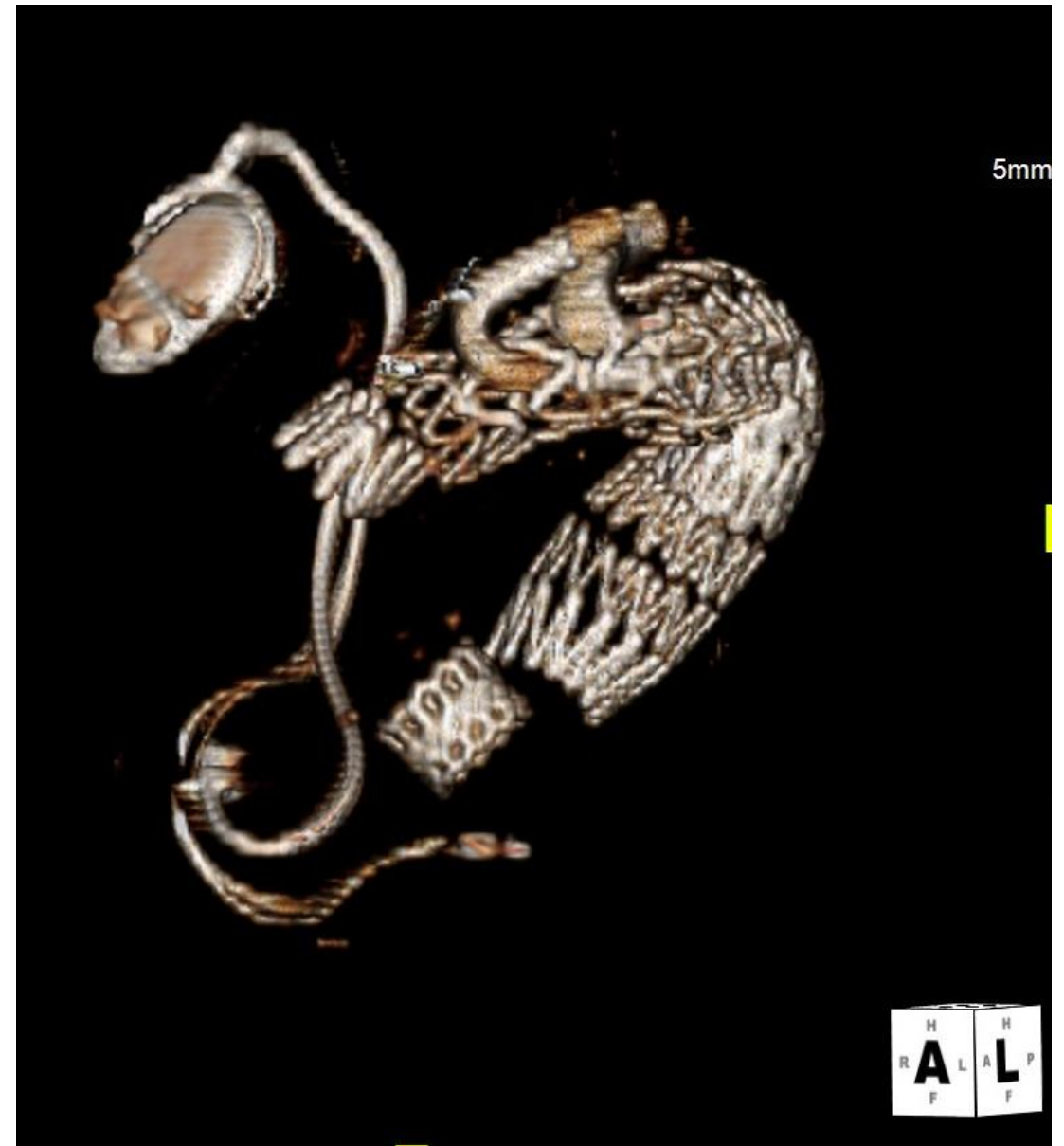
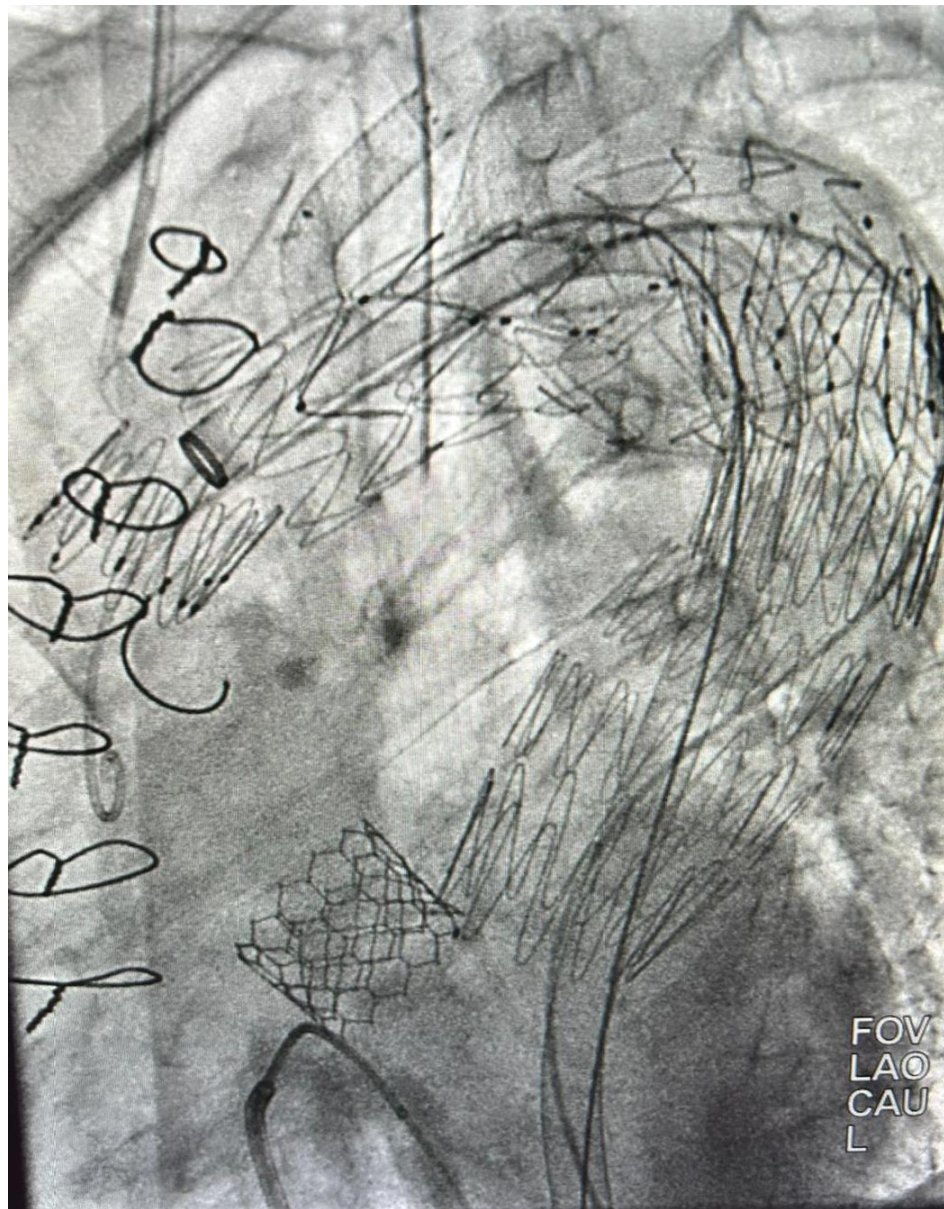Saint-Joseph

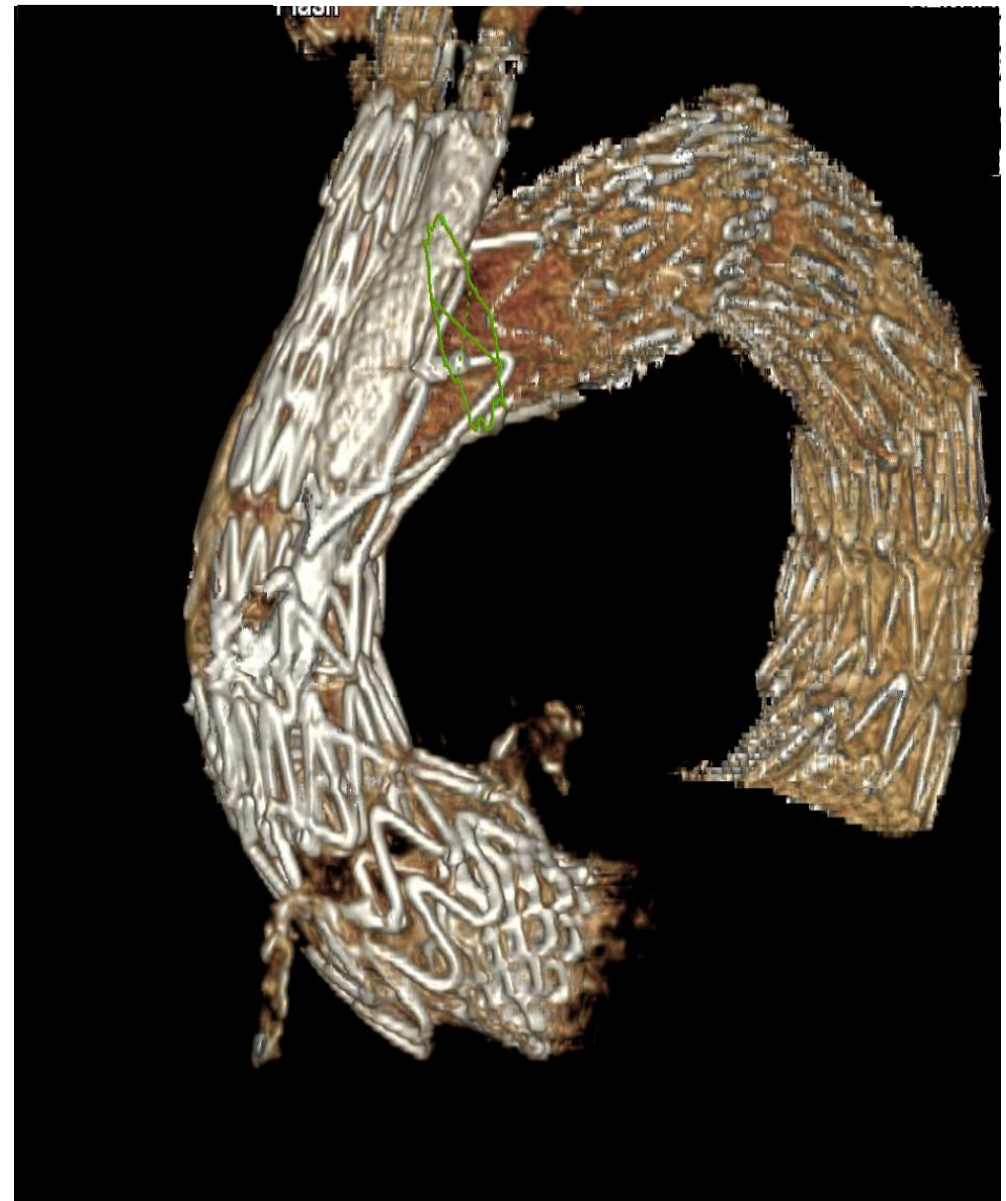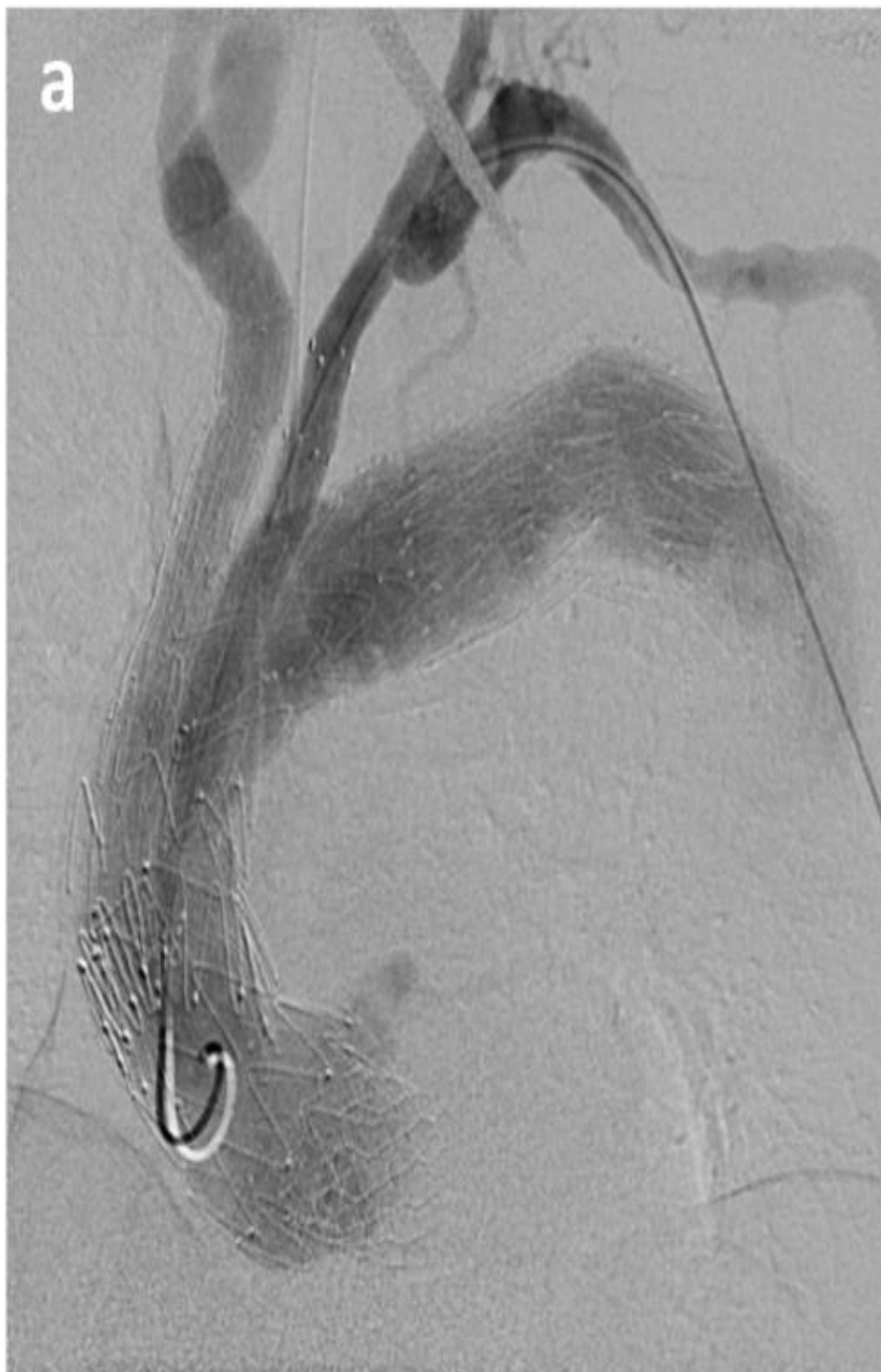Marie-Lannelongue

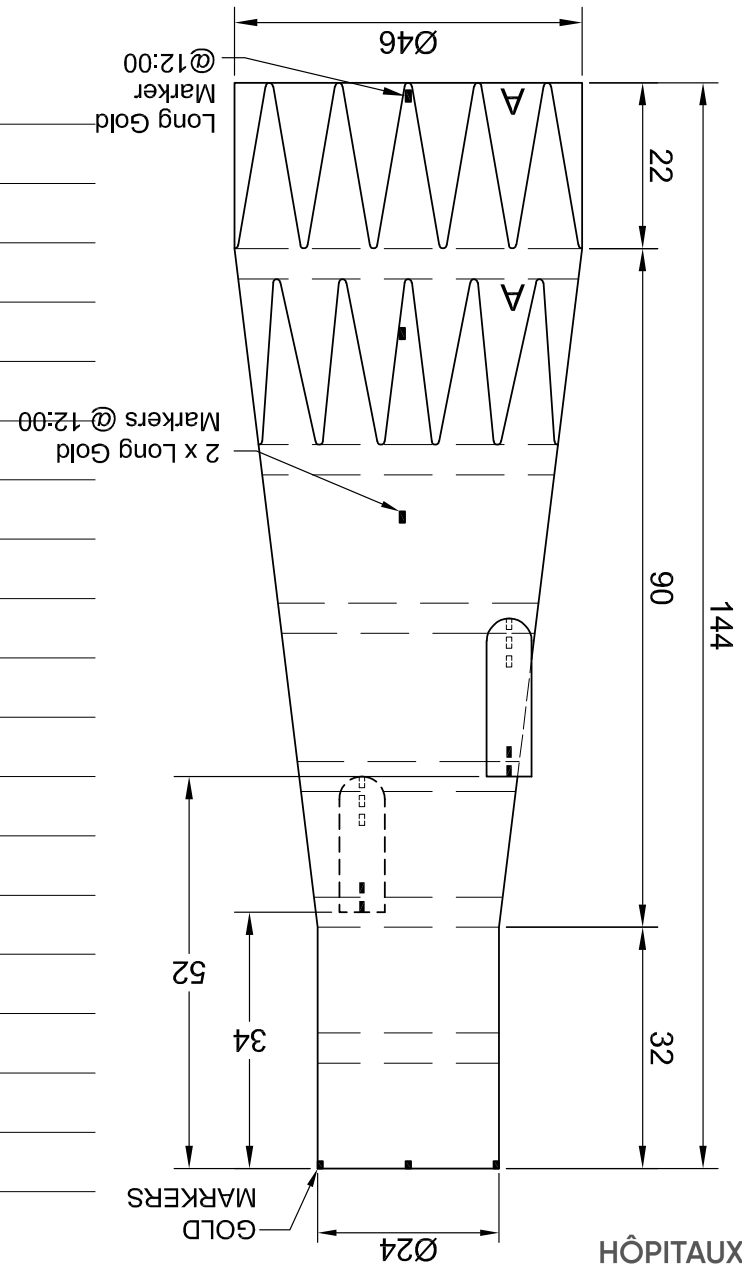
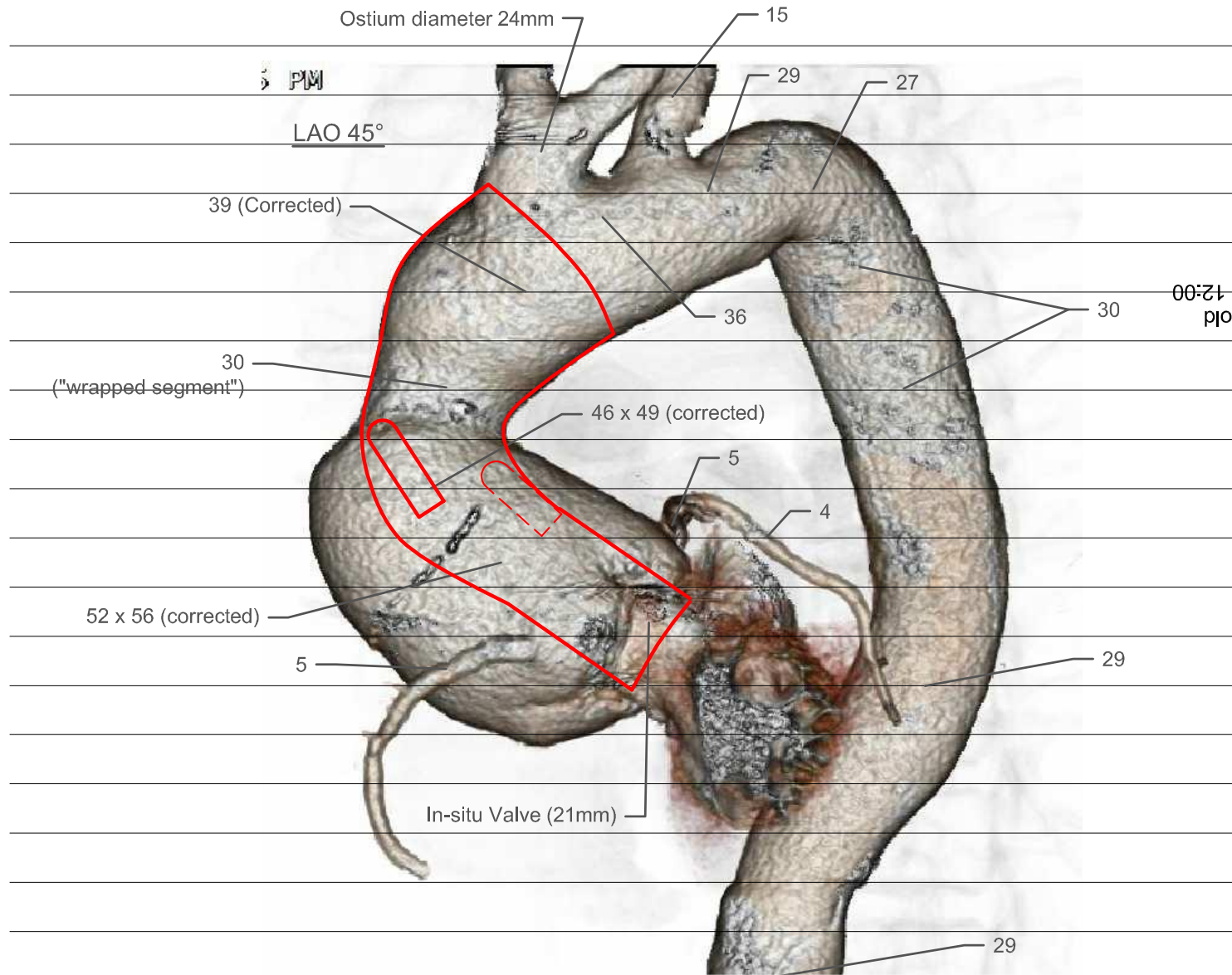




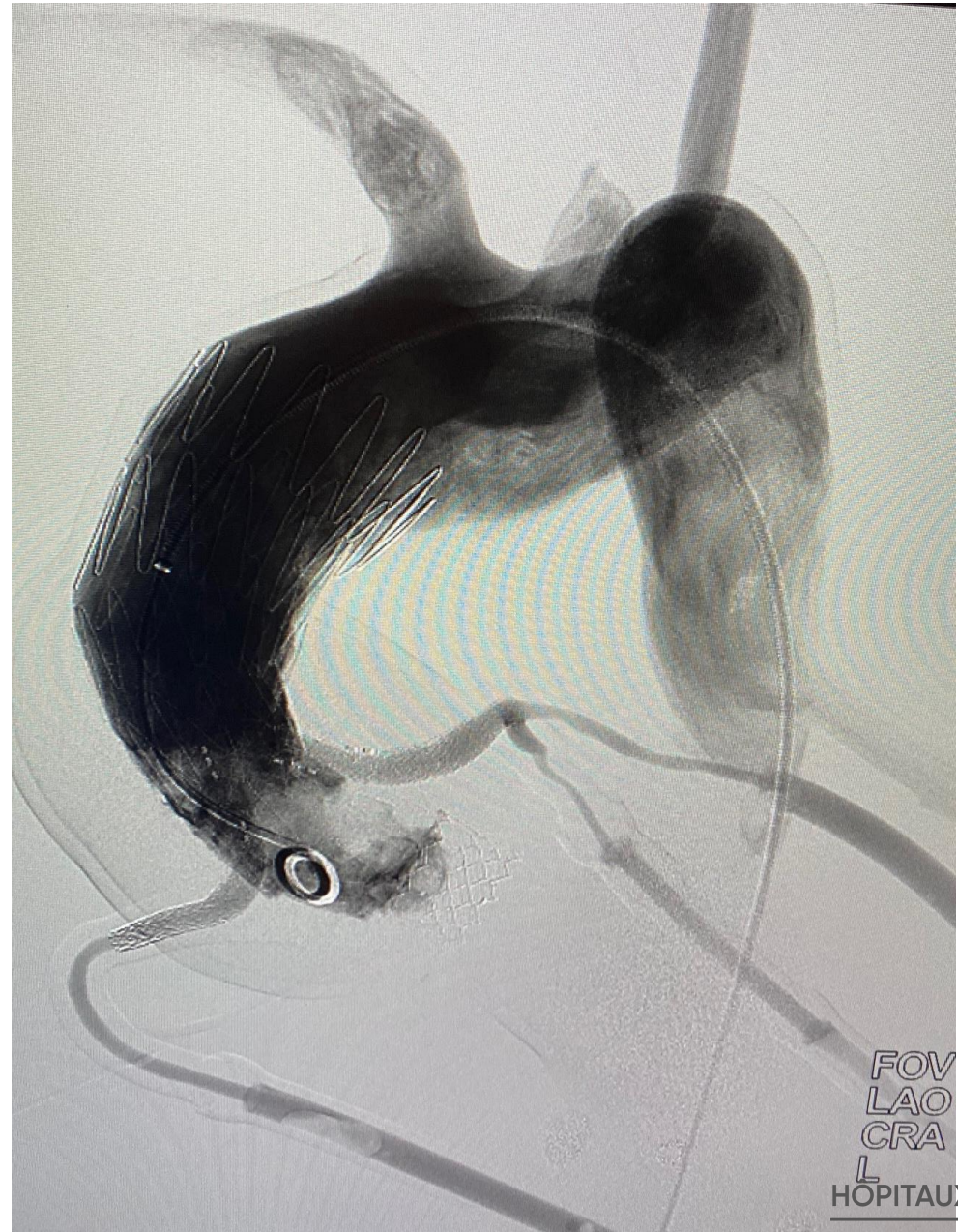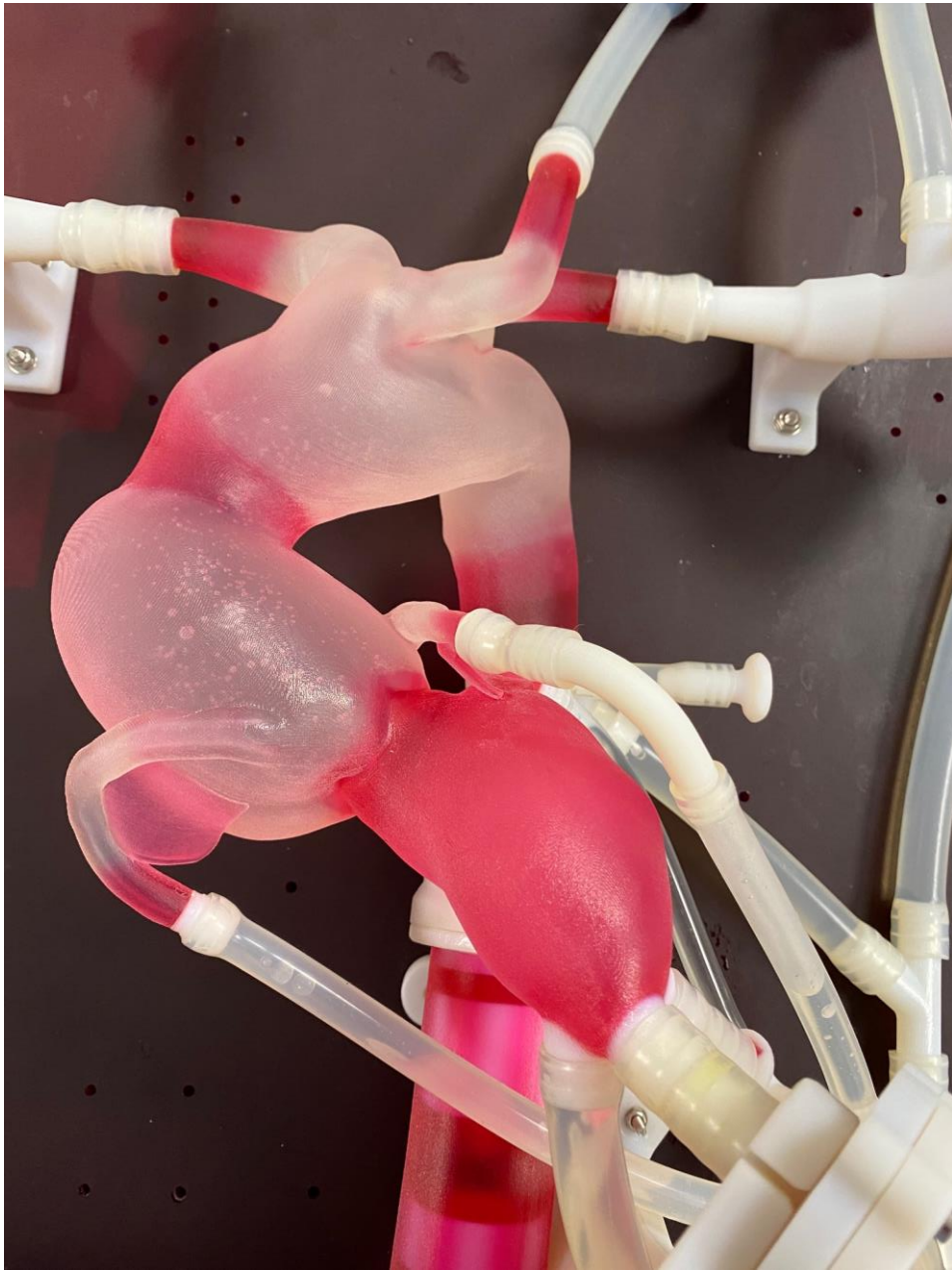


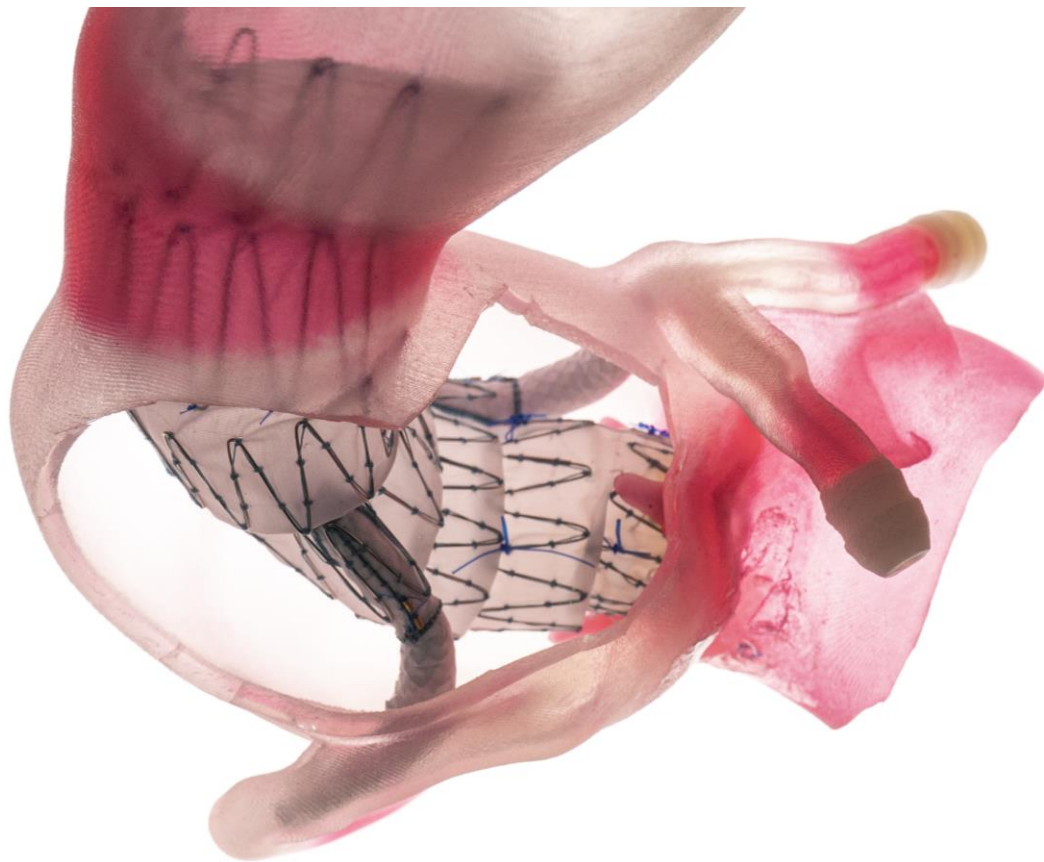
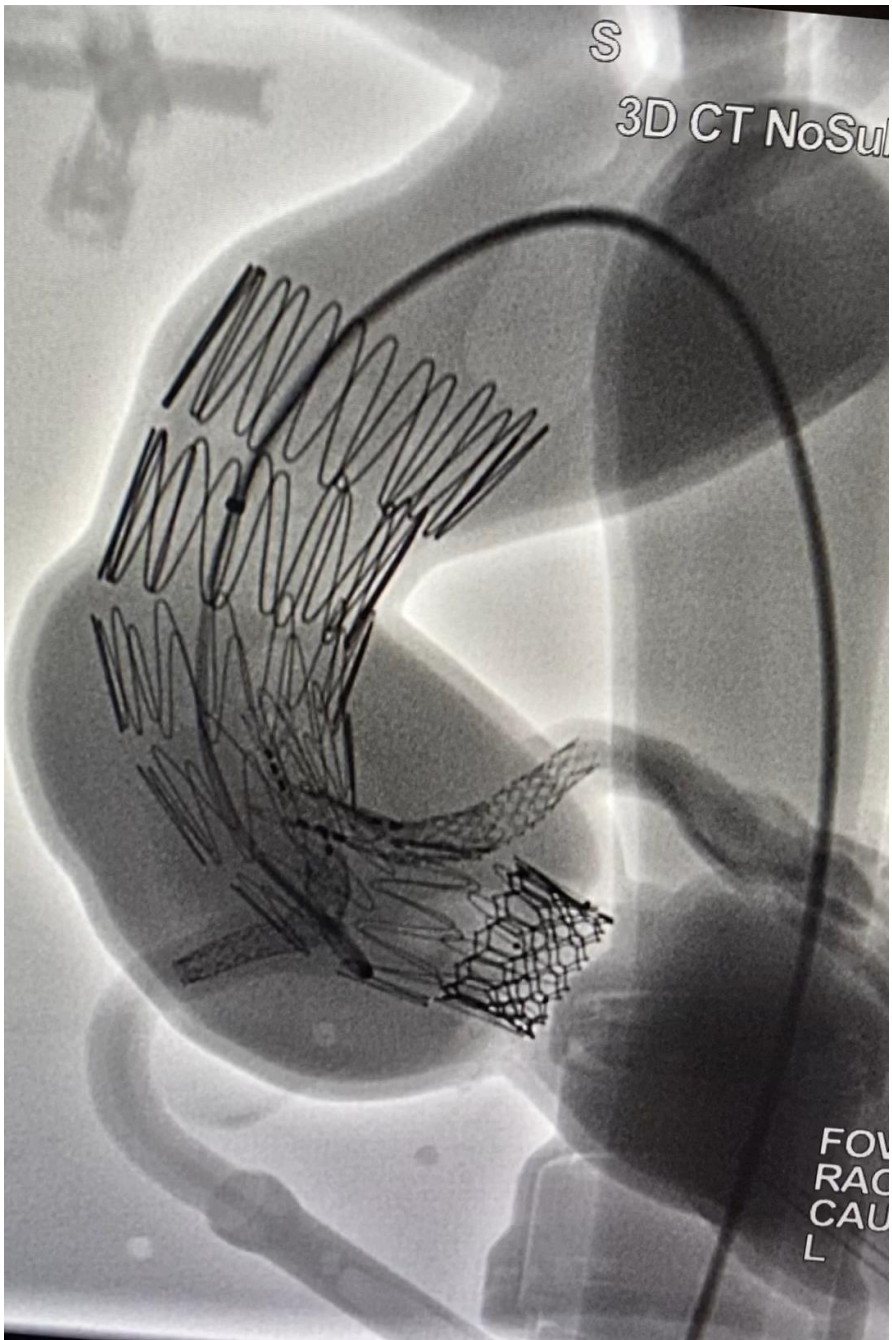


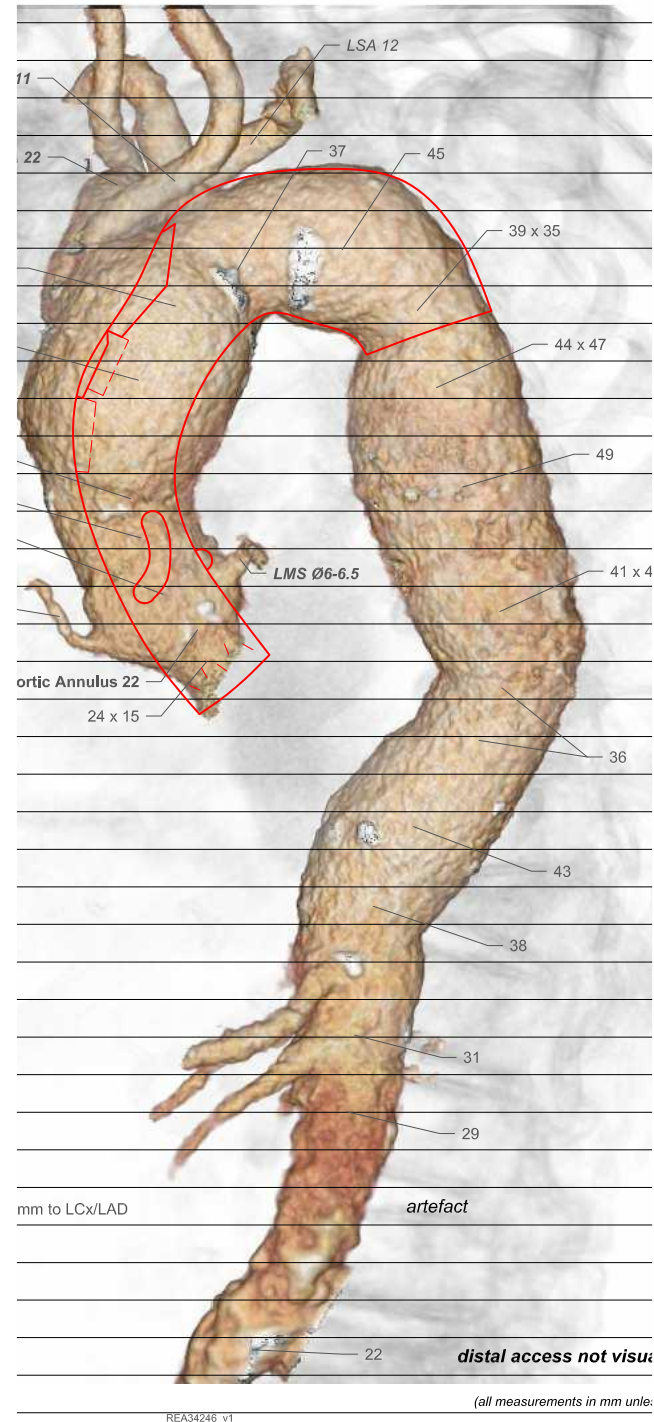
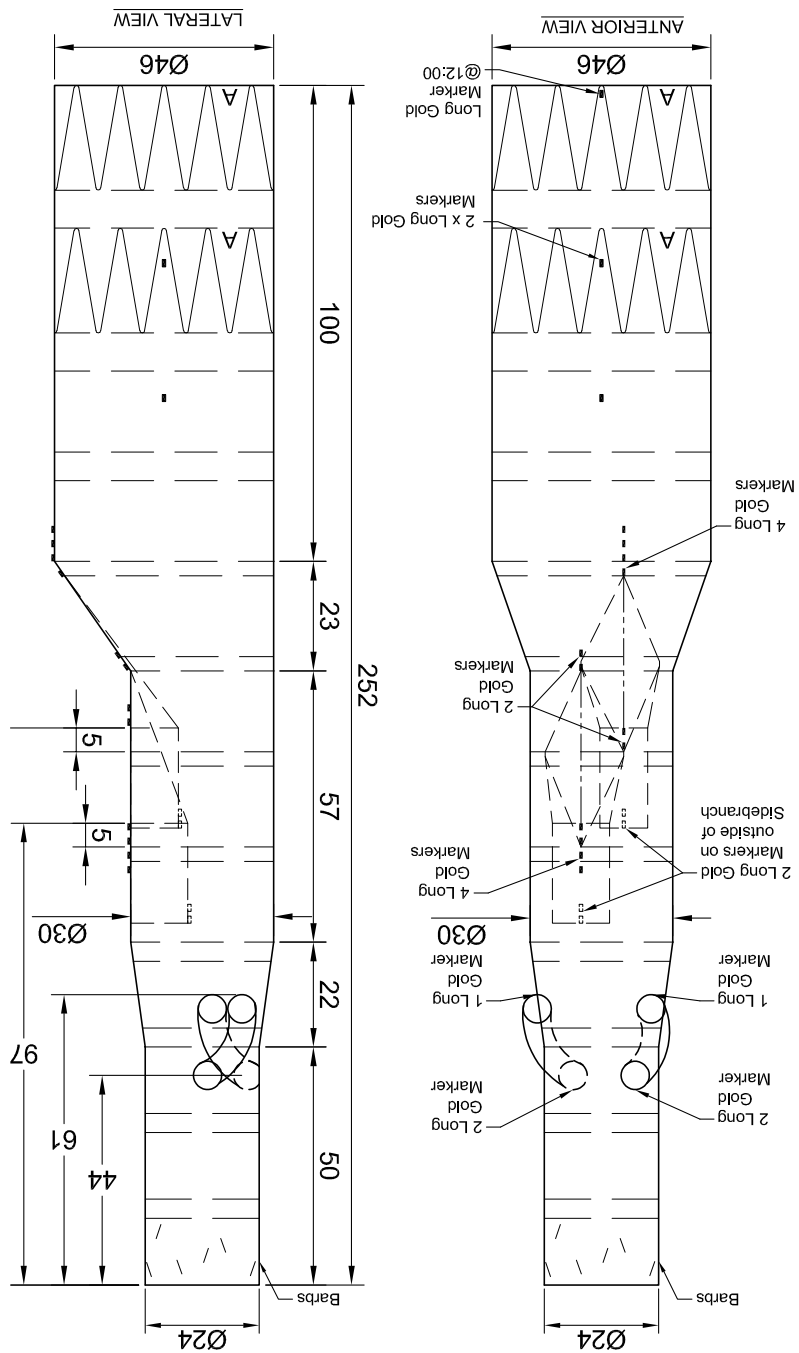




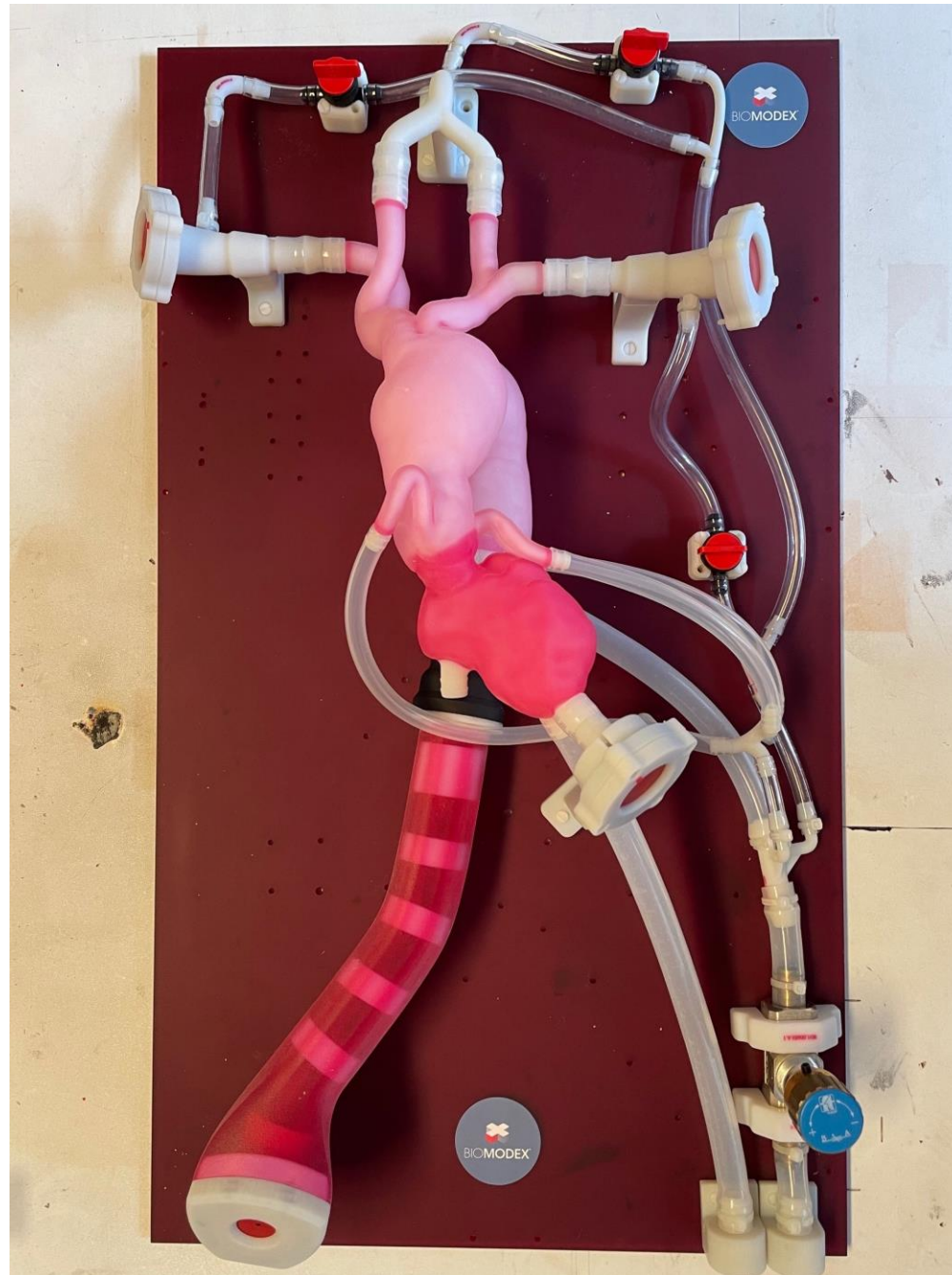



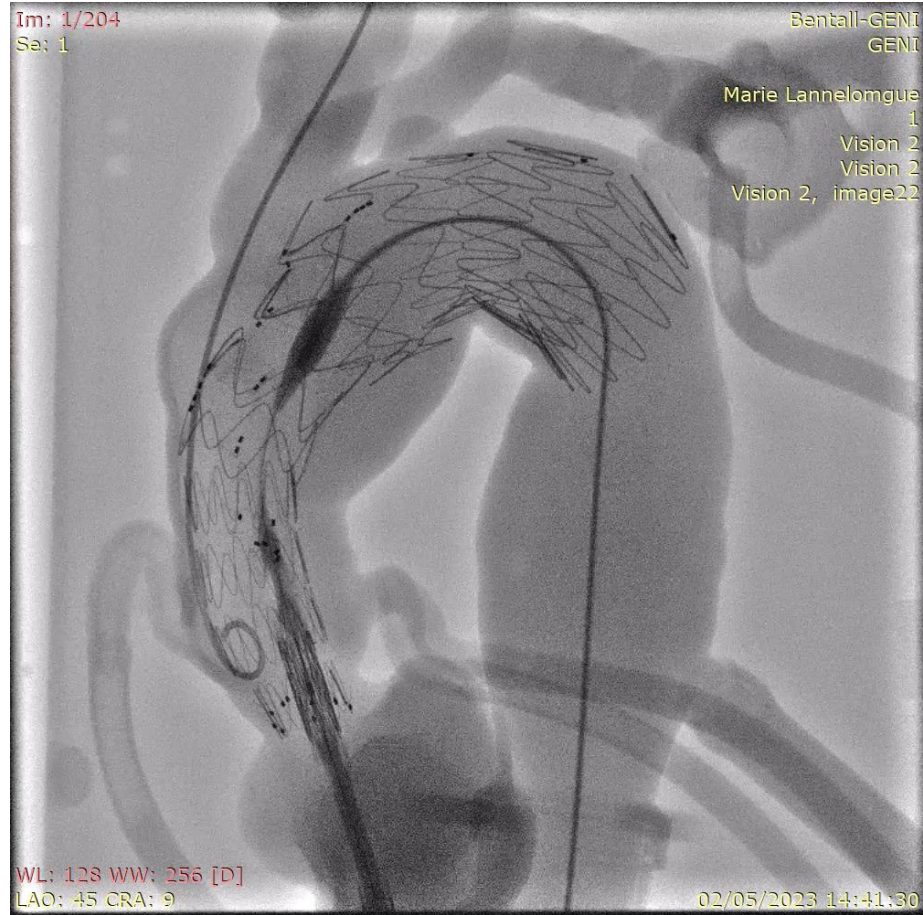


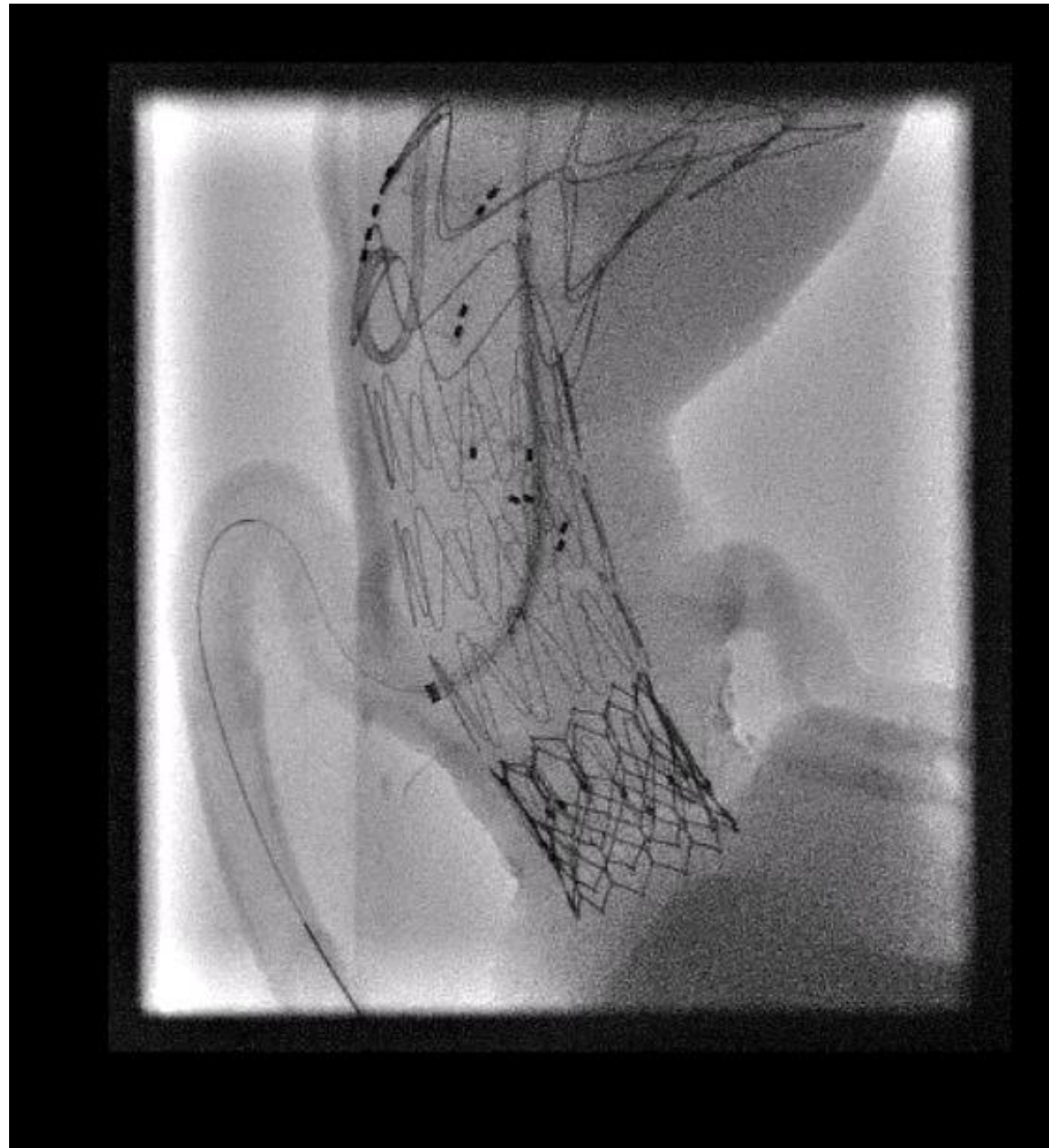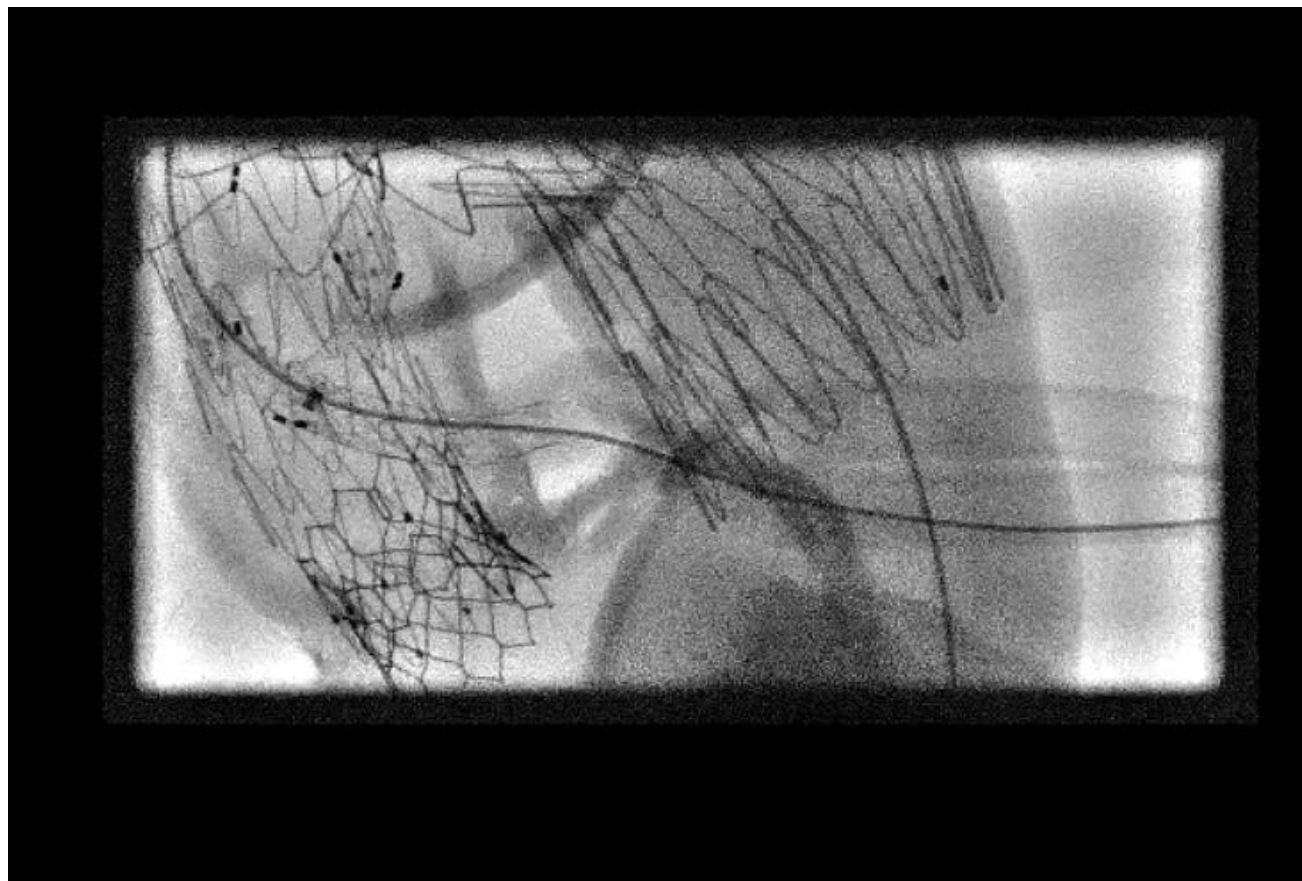


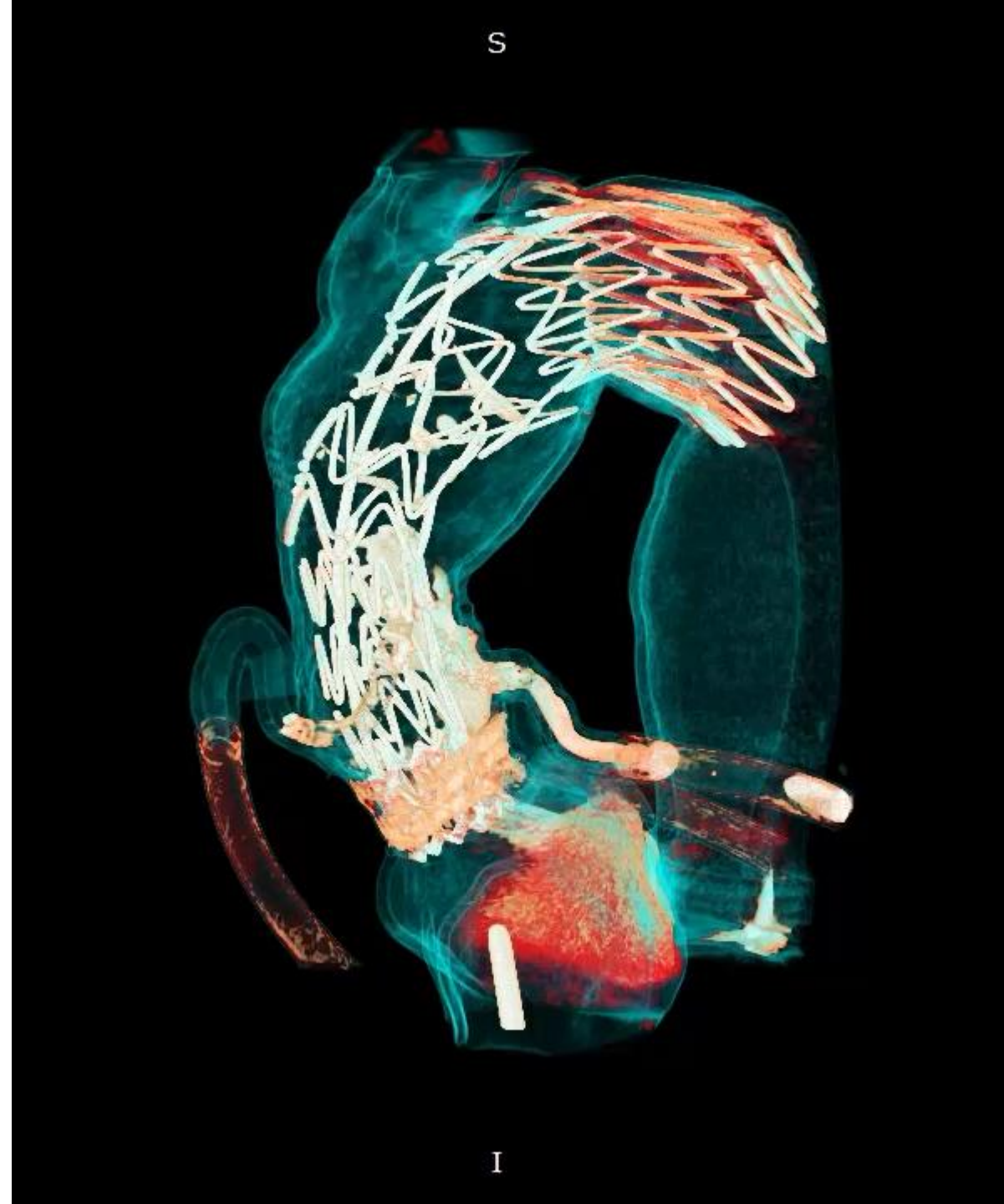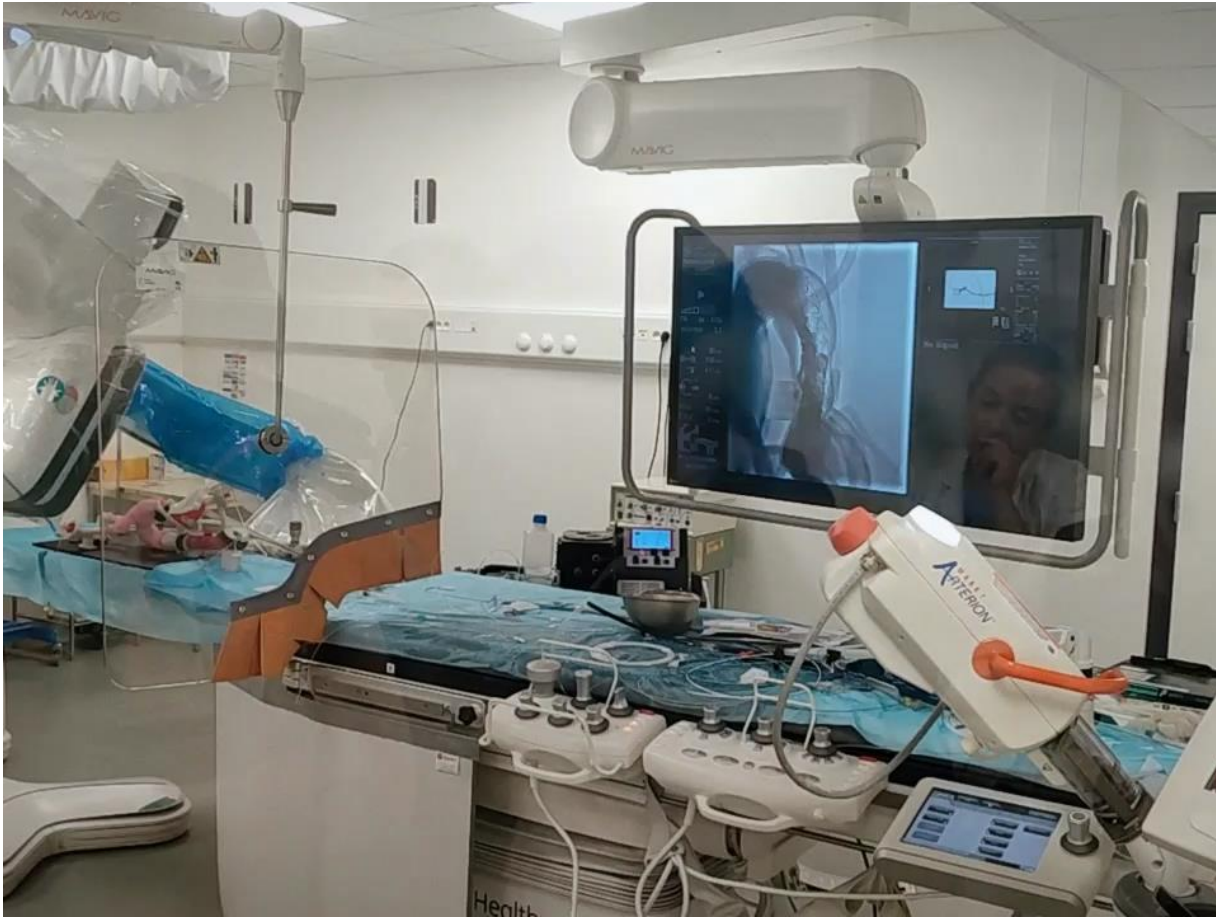Pr A. Millon  
 CHU Lyon,  
 Fr





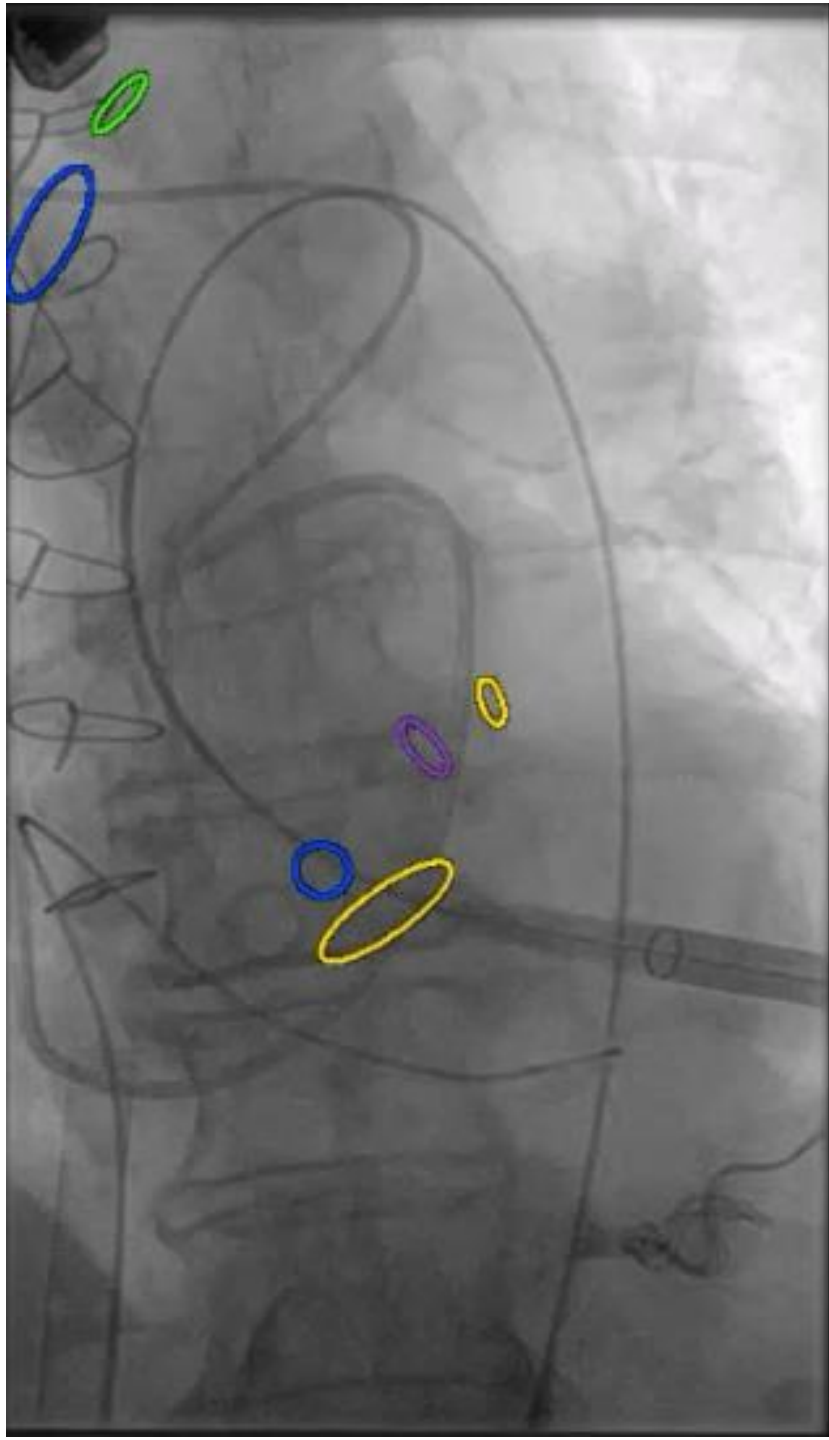


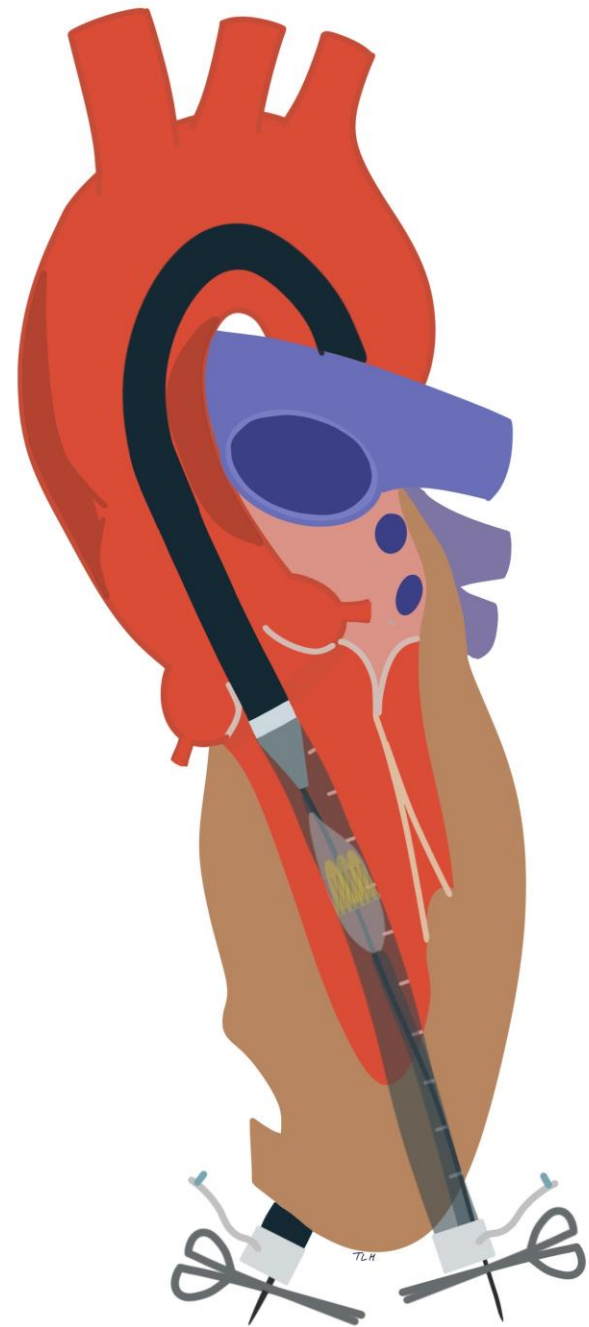
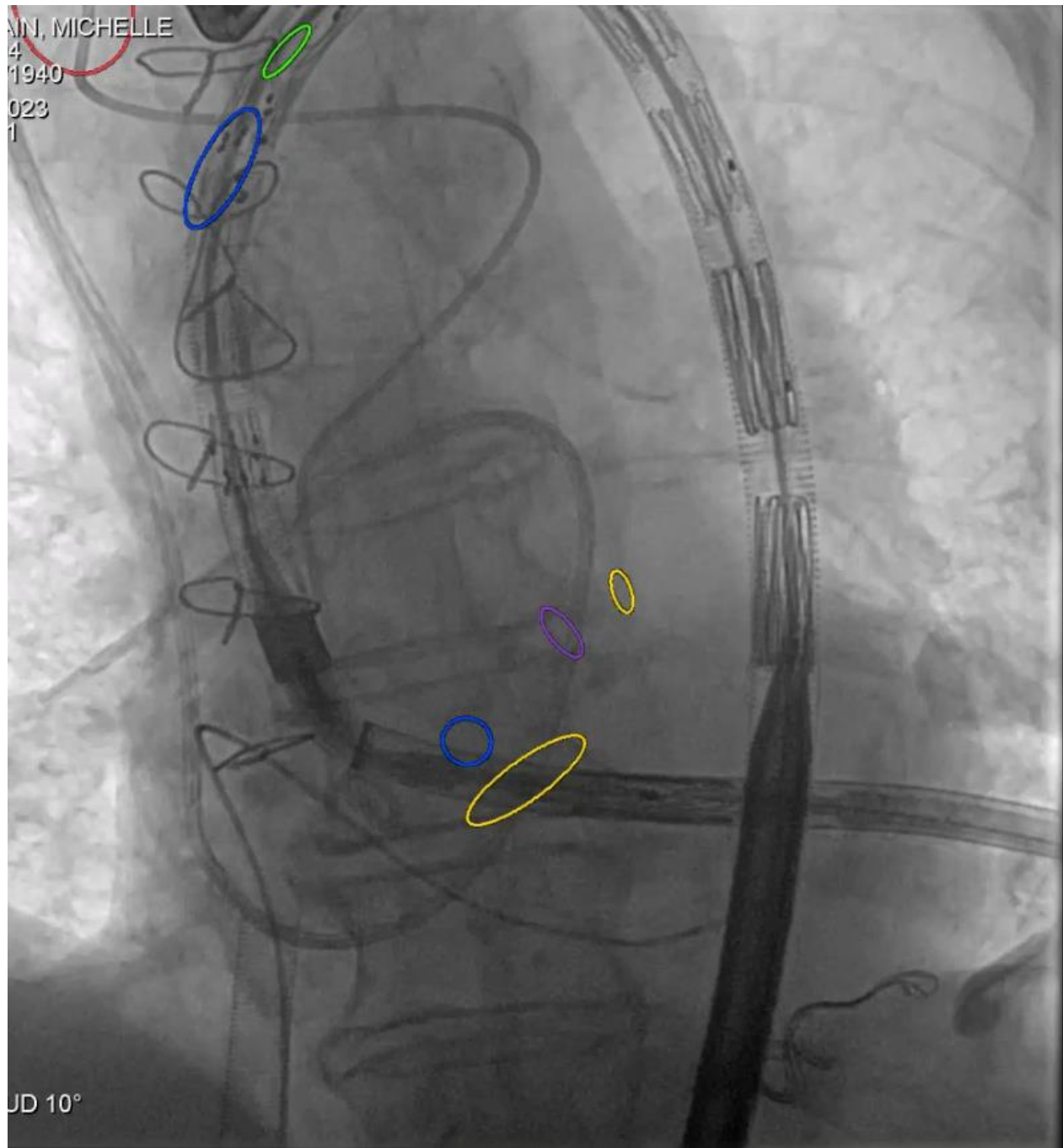


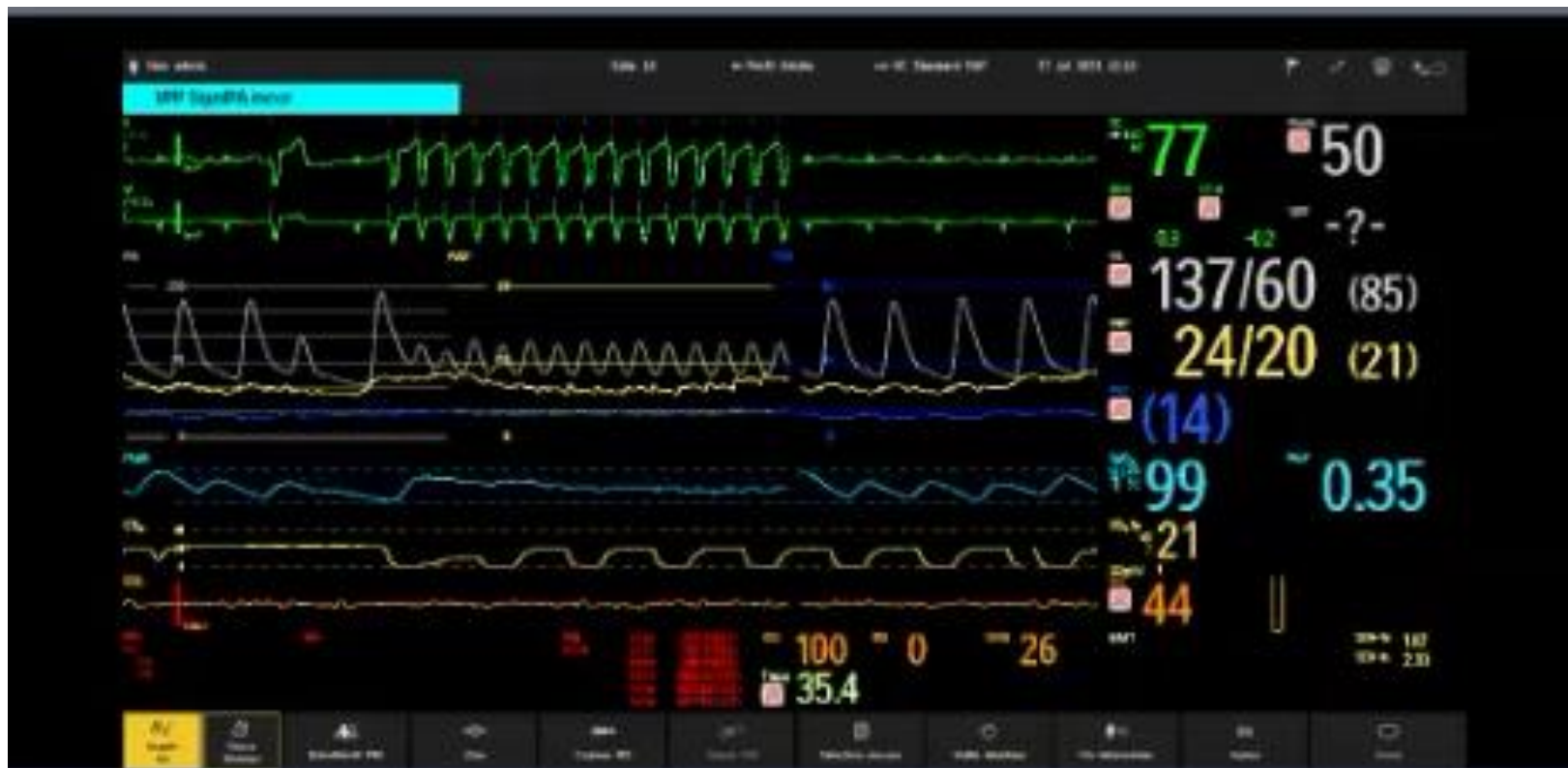

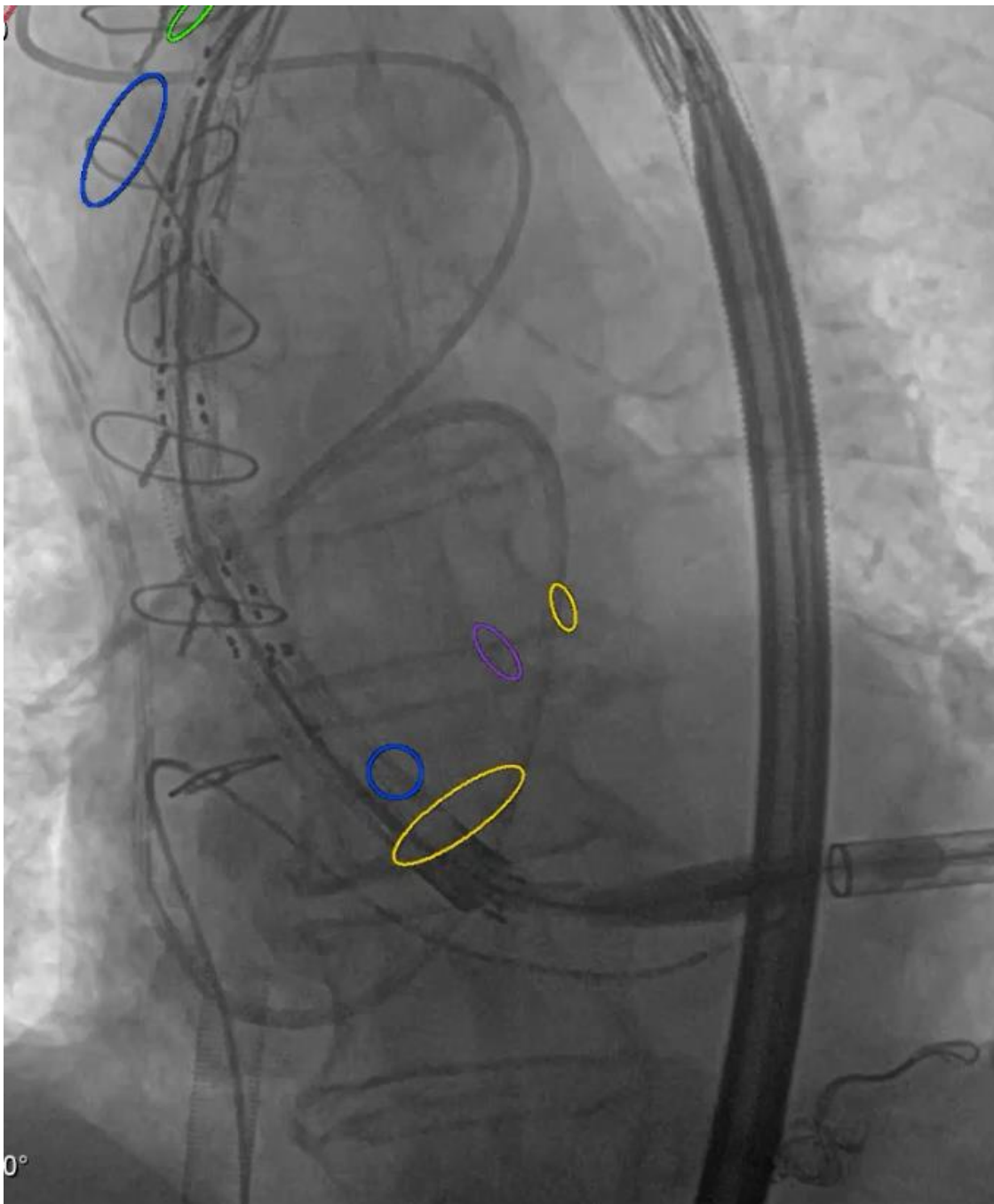


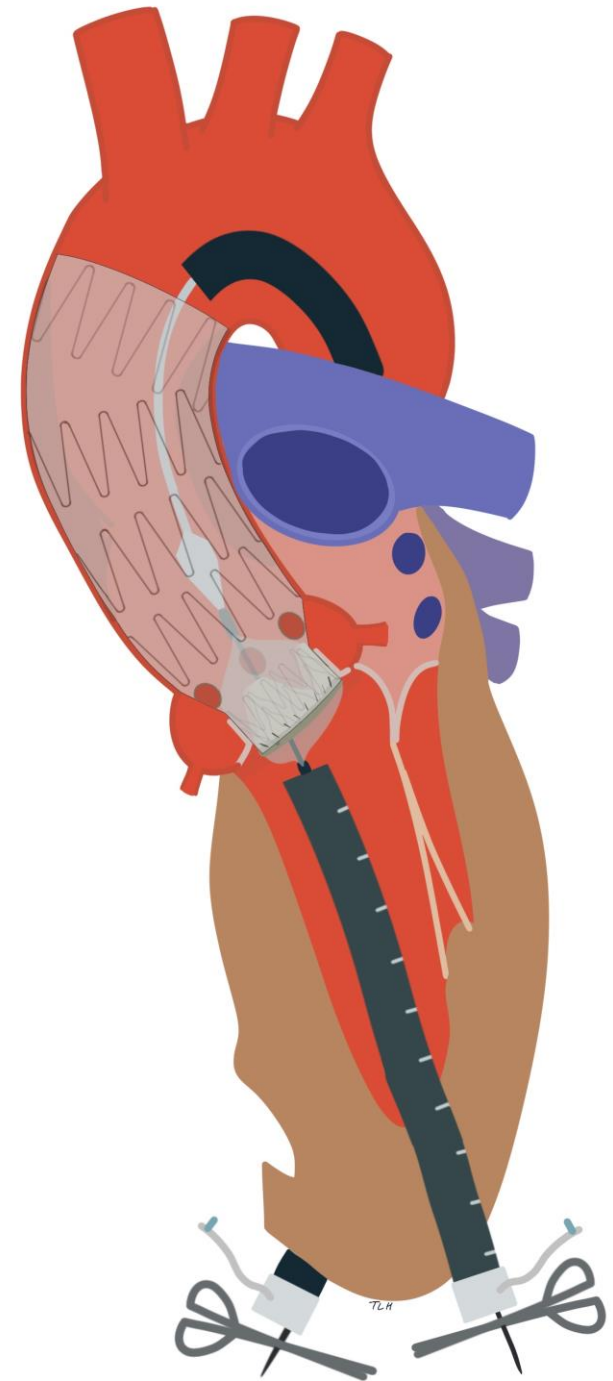
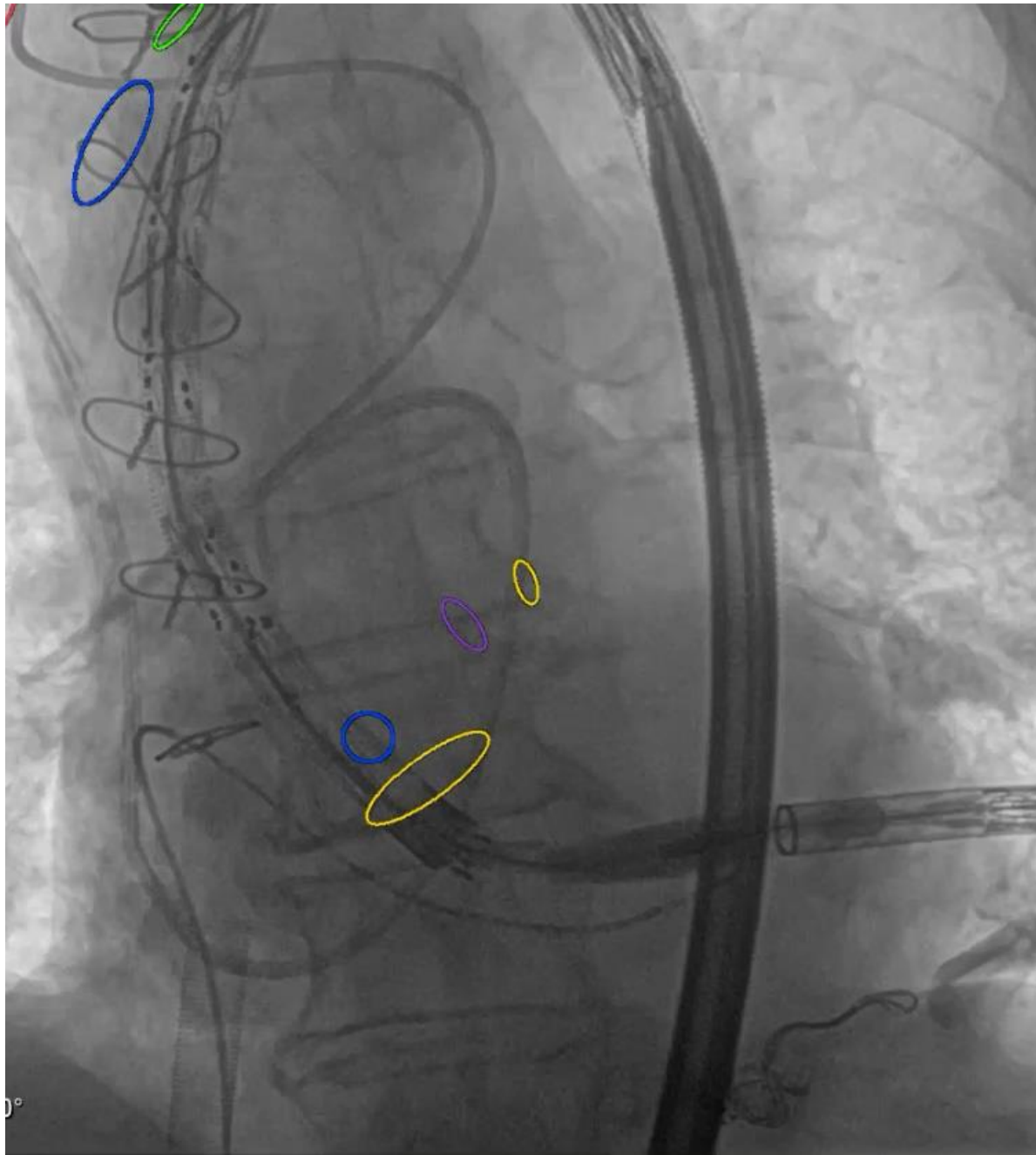


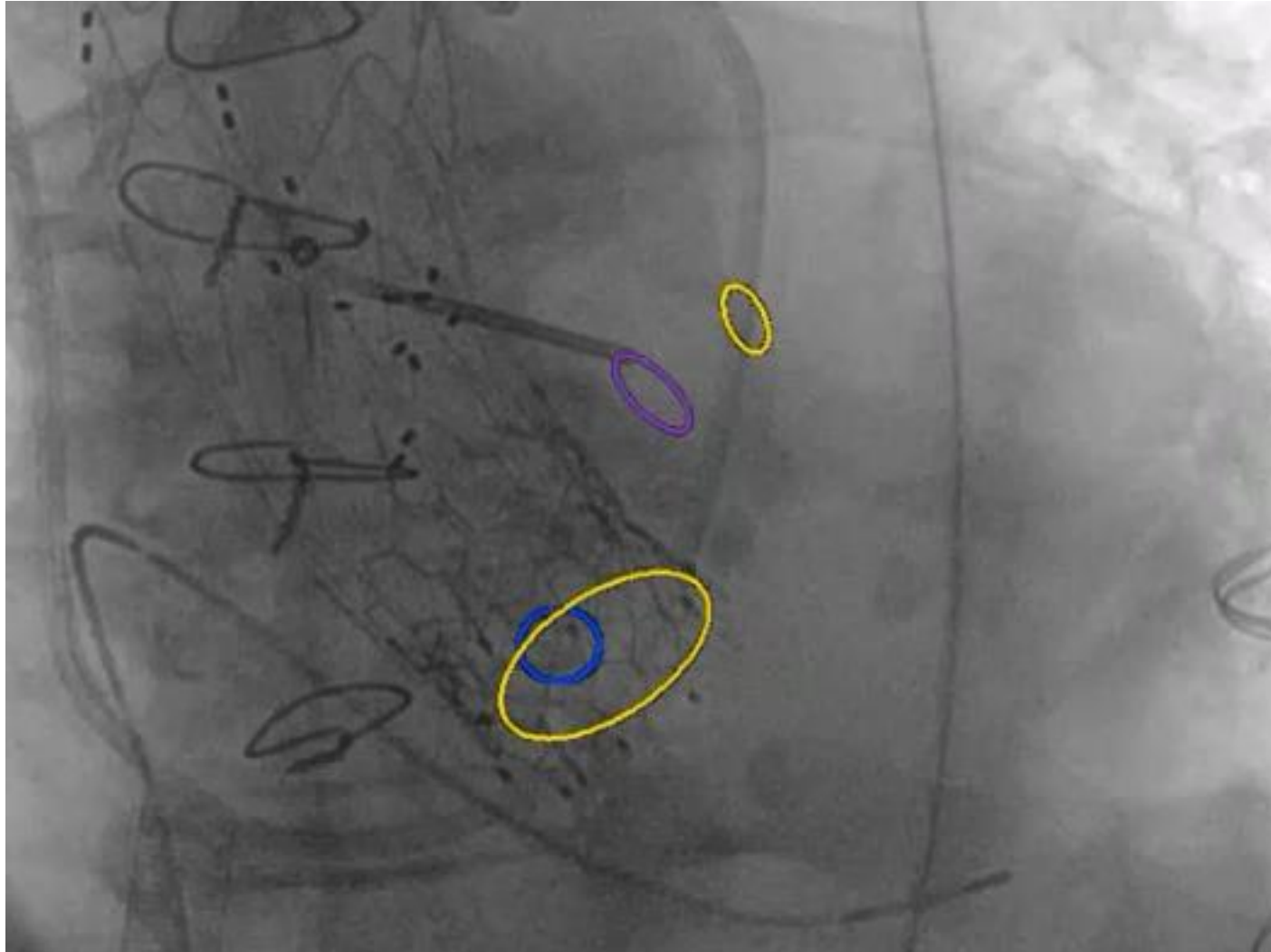


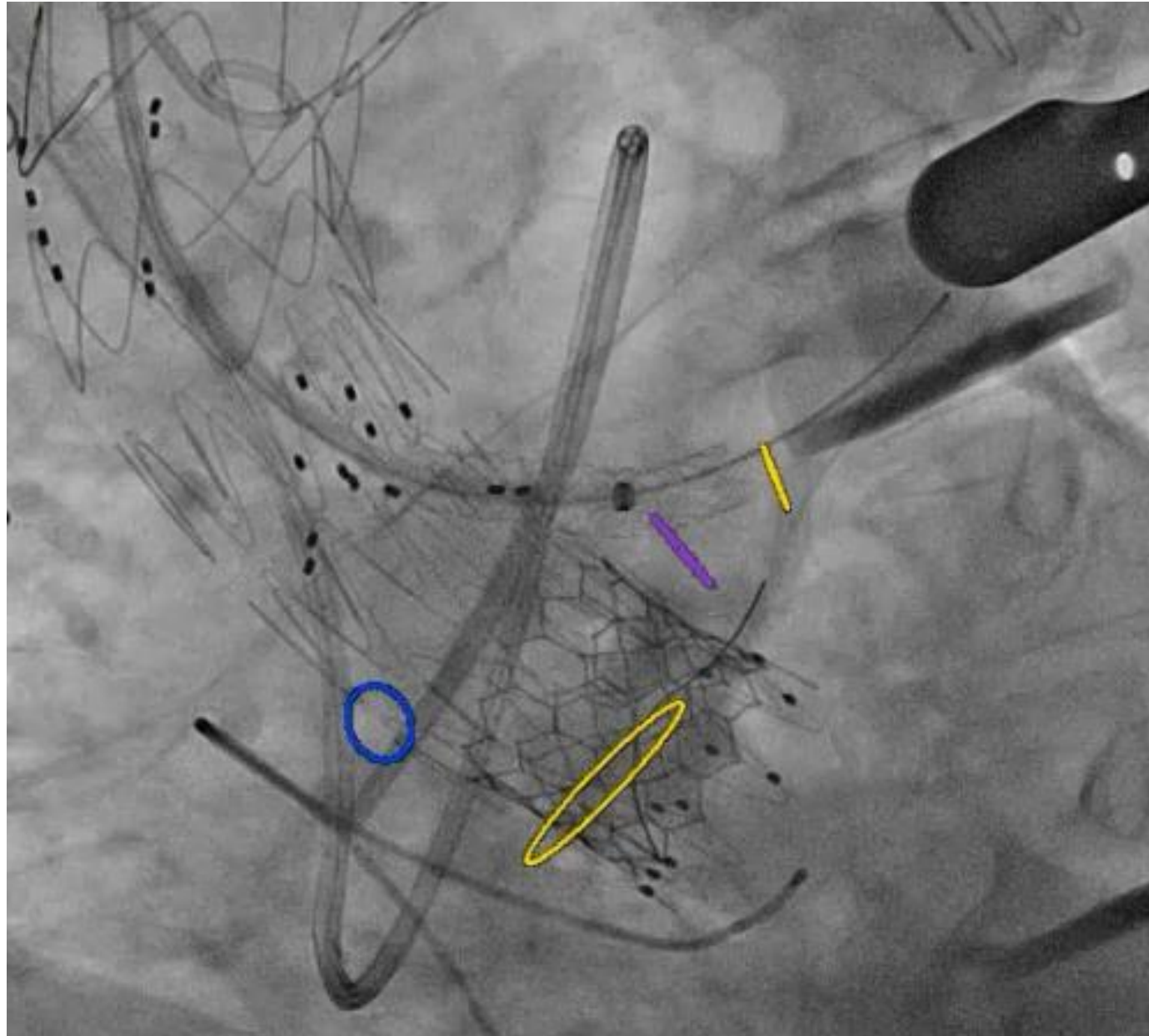




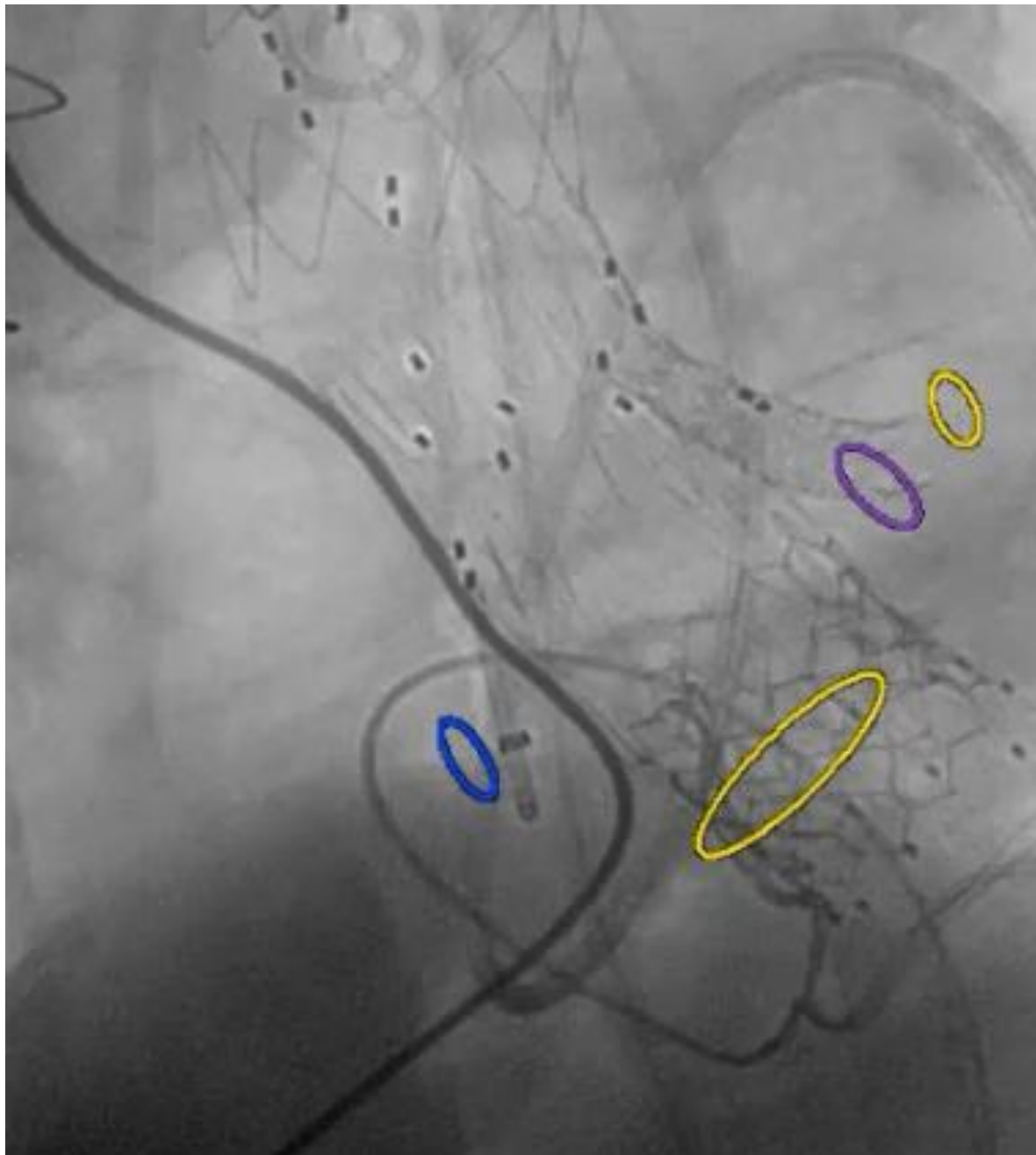



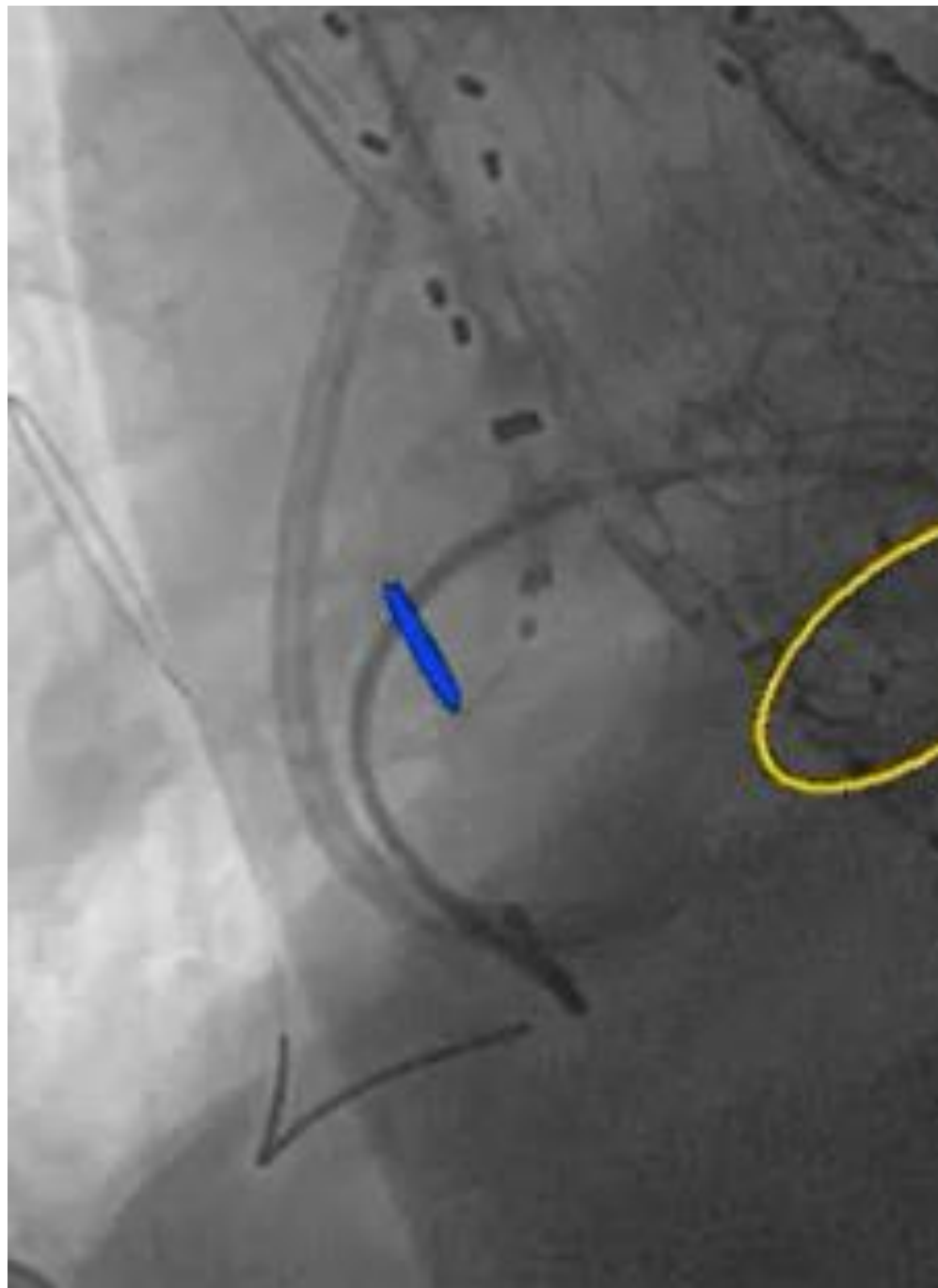



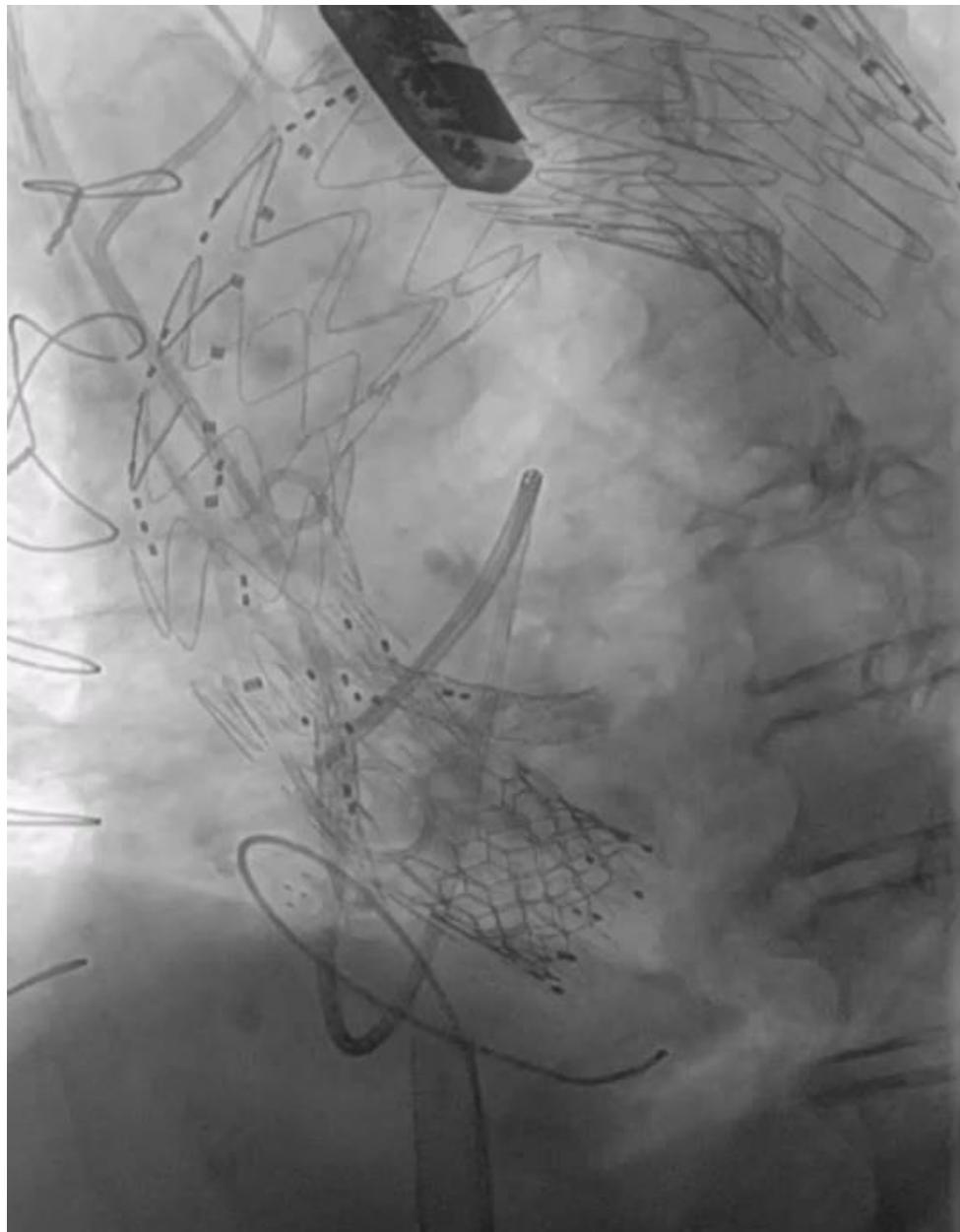


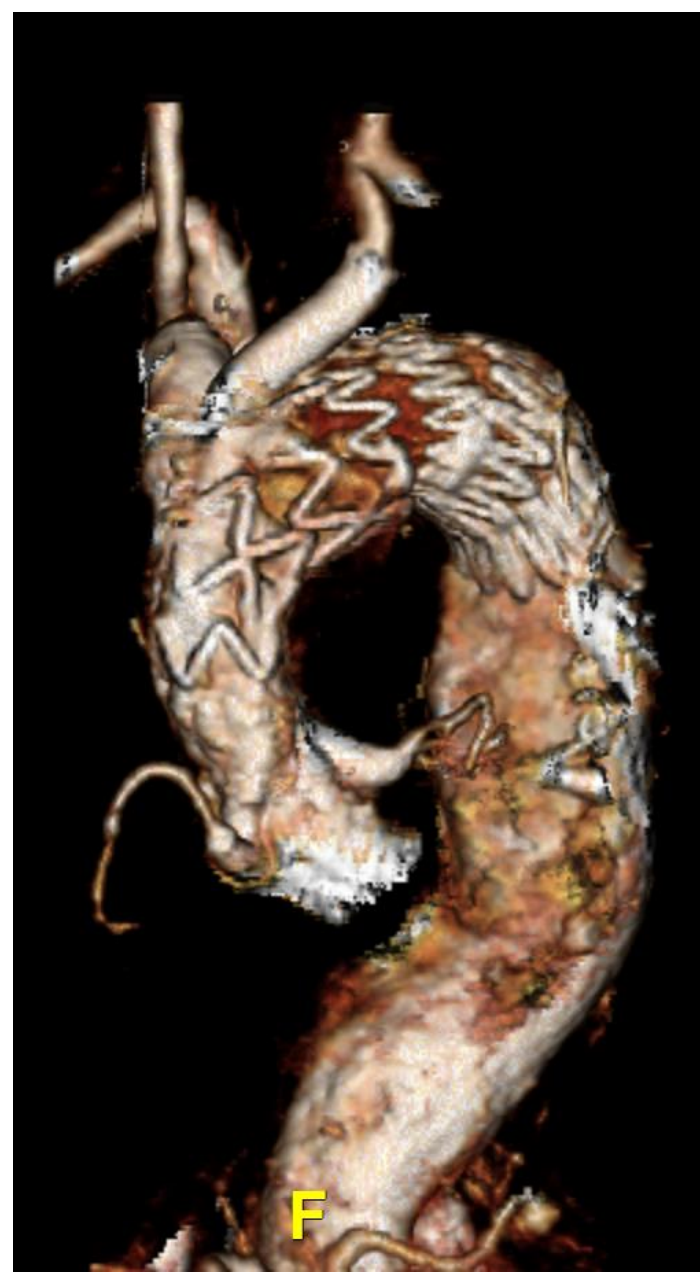
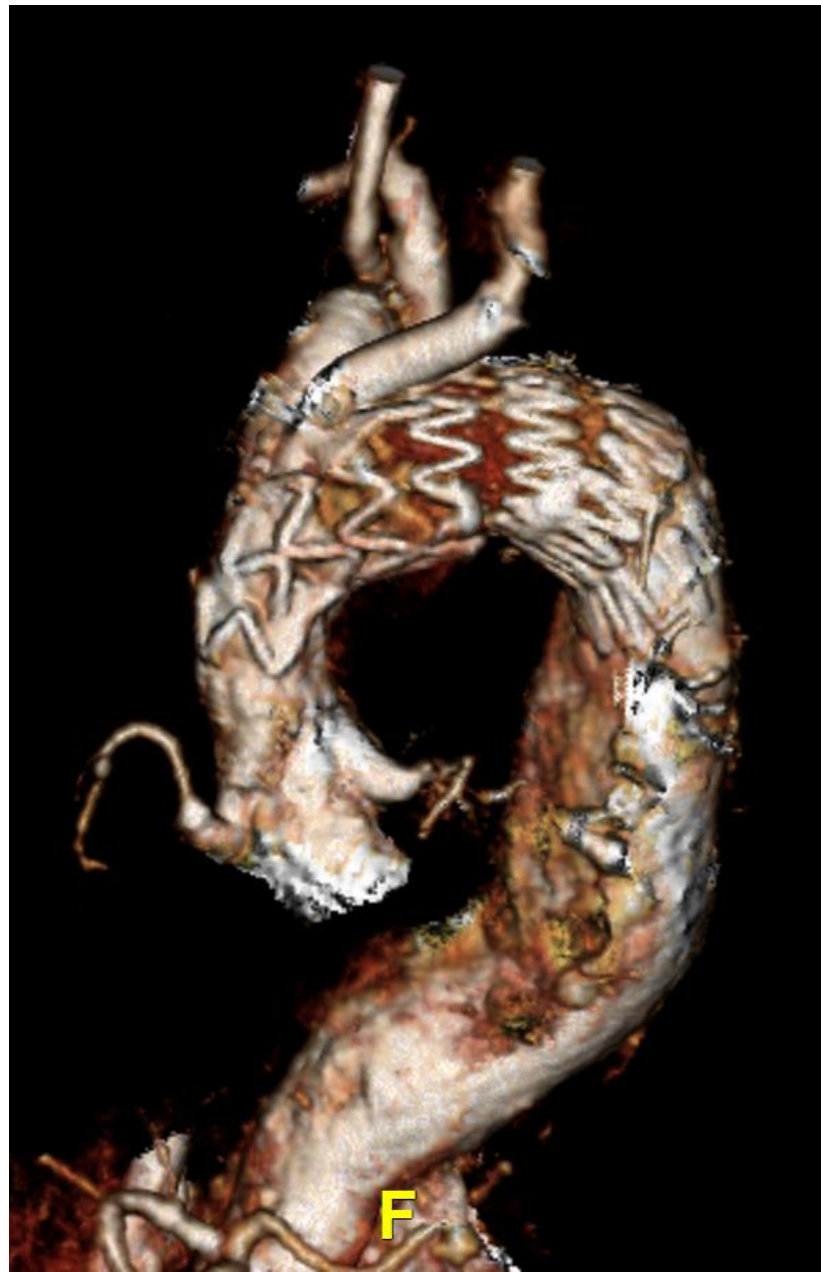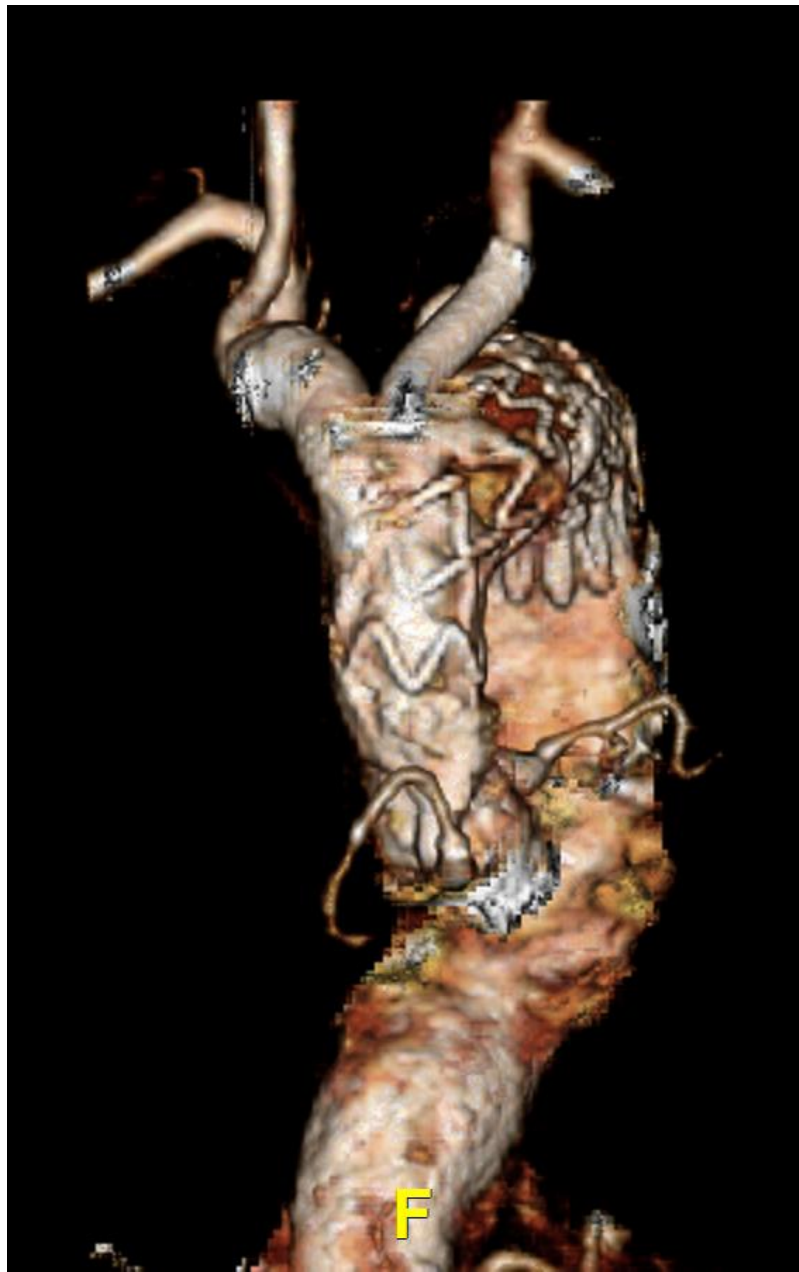










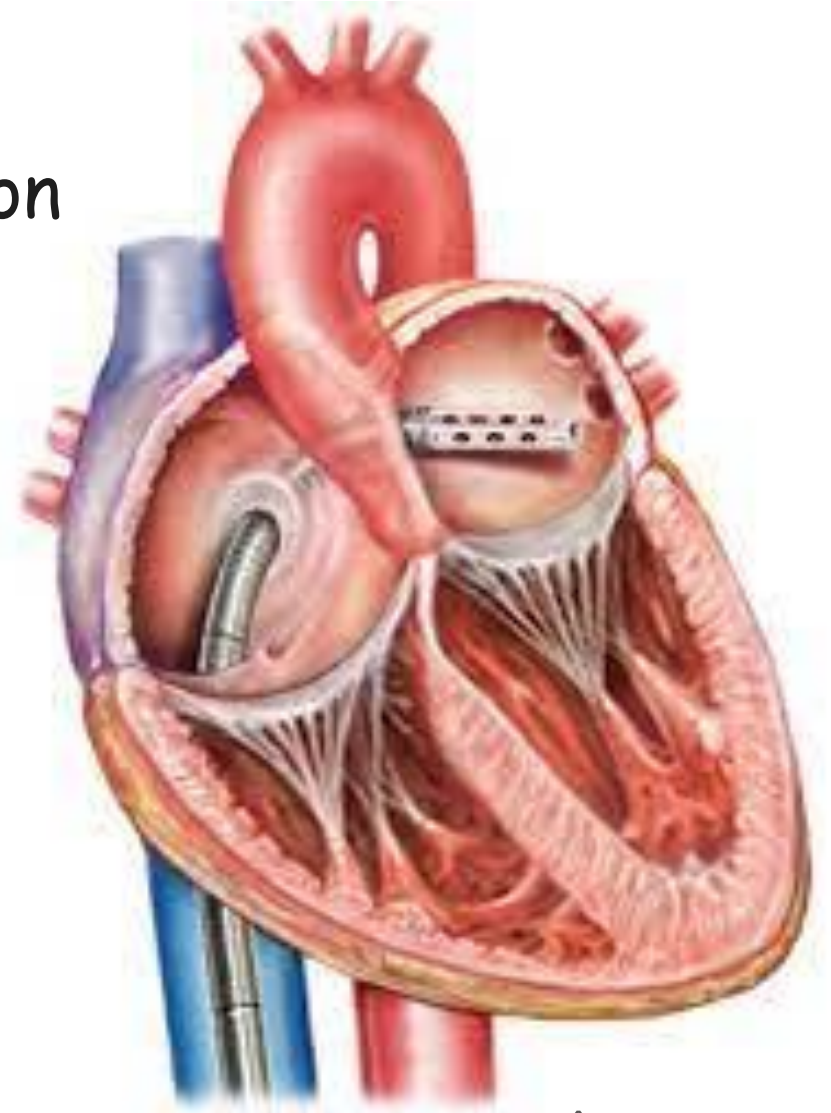


# Minimal Invasive Repair?

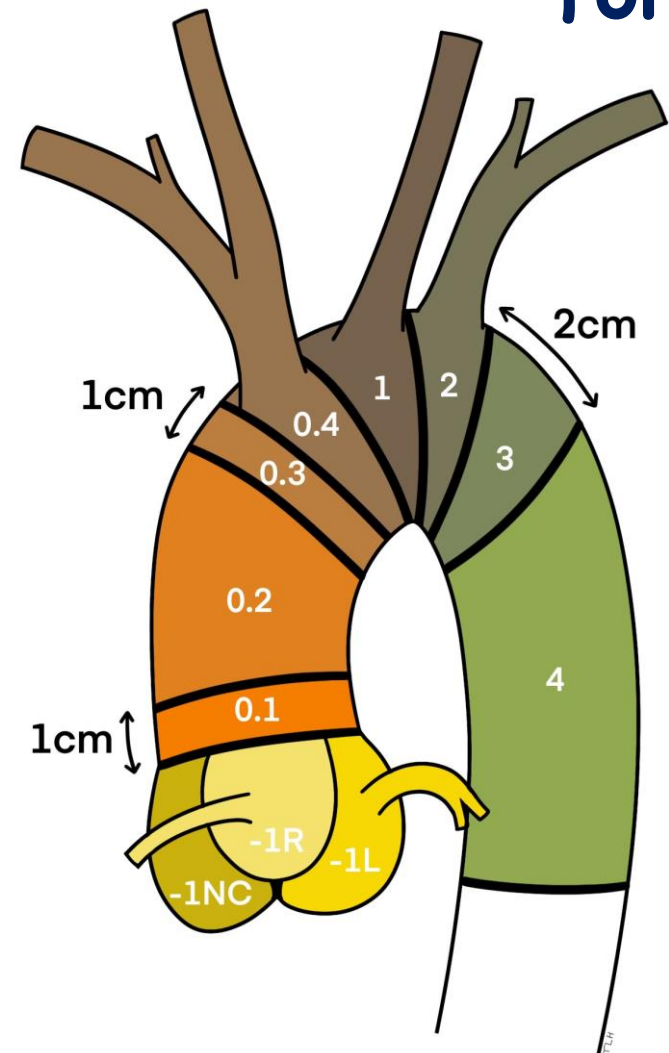
- TransApical (abandoned for TAVR)
- Left femoral A&V ECMO + right femoral 24Fr sheath = infra renal aortic clamp
- Low flow from major LV bleeding resulted in acidosis & major lactate increase
- 82 year-old woman with cirrhosis

# TANDEMHEART®

- Percutaneous left ventricular unloading option



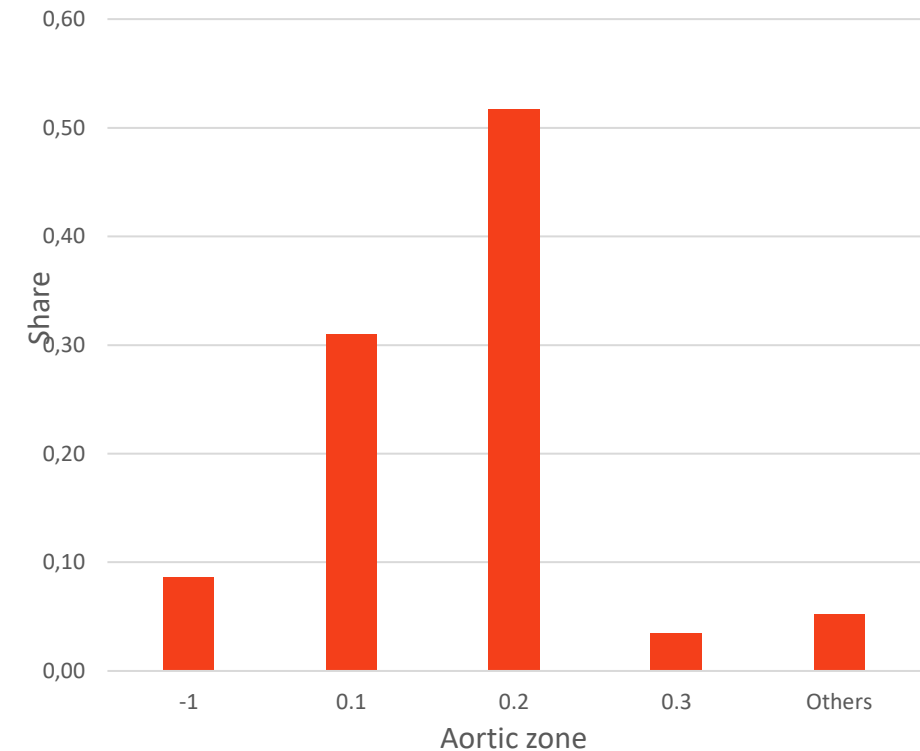
# Anatomic feasibility of FBEVAR Endo-bentall treatment for acute type A aortic dissections



250 CT scans

Mean aortic annulus:

- diameter was 26.71mm (+/-3.71)
- perimeter was 87.7mm (+/- 17.7)
- surface was 571.2 mm<sup>2</sup>(+/-168.2)

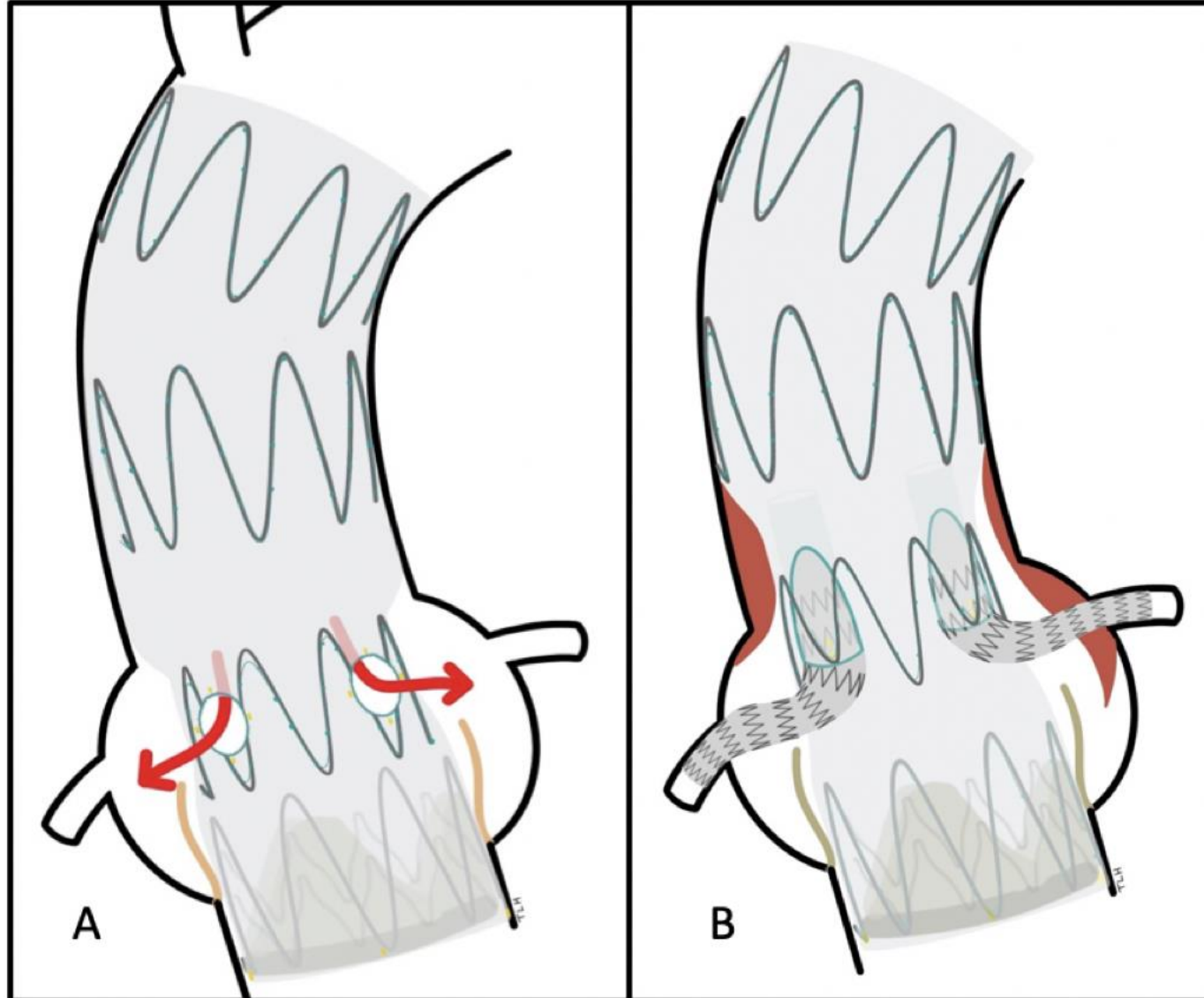


A. Vallée et al - Retrospective study in 3 aortic French centers (Marie Lannelongue, Lille, Nantes)



# Acute Type A dissections: Two treatment options

Fenestrated  
Endobentall  
49.3%



Branched  
Endobentall  
24.2%

